



## Ascending colon adenocarcinoma presenting as appendicitis

Adejumo AA<sup>1</sup>, Alegbejo-Olarinoye MI<sup>2</sup>

<sup>1</sup>Department of Surgery (General Surgery), Federal Medical Centre, Keffi, Nassarawa State.

<sup>2</sup>Department of Surgery (General Surgery), University of Abuja, FCT.

### Abstract

**Background:** Appendicitis is a pathology that occurs more in the younger population. The occurrence of appendicitis in the middle aged is uncommon and presentations may be sinister to other causes. The clinical presentation of appendicitis in our index patient with incongruous laboratory findings prompted further evaluation that eventually revealed the underlying cause.

**Method:** A middle-aged man presented with features of recurrent appendicitis with equivocal laboratory work-up. Abdominal sonography as well as computerized tomograms (CT scan) were done as well as colonoscopy.

**Result:** Abdominal sonography was inconclusive and contrast-enhanced CT scan done was suggestive of appendicitis as a stenosing lesion of the proximal right colon. Colonoscopy done revealed proximal ascending colon tumor which was biopsied with histopathology report of adenocarcinoma.

**Conclusion:** The unusual occurrence of appendicitis in the middle-aged should prompt the likelihood of an underlying pathology hence; the surgeon should always broaden his mind when evaluating such.

Keywords: Middle-age, Ascending colon, Appendicitis, Radiology, Colonoscopy, Adenocarcinoma.

### Introduction

Appendicitis is the inflammation of the vermiform appendix. This clinical condition is more common in the younger age group and found to be rare at extremes of life. The occurrence of appendicitis is usually preceded by luminal obstruction from various factors. Obstruction of the appendiceal lumen could trigger the process of inflammation. This is usually caused by faecolith, ova of parasites, kinking of the appendix by fibrous bands or lymphoid hyperplasia.<sup>1,2</sup>

The fate of an inflamed appendix therefore depends on the age of the patient, the duration of symptoms, degree of obstruction and adequacy of vascularity hence; appendicitis could be catarrhal, suppurative, gangrenous or rupture with local or generalized peritonitis.<sup>3</sup>

However, an uncommon clinical presentation of appendicitis is when there is associated caecal or ascending colon diseases such as malignancy.<sup>4</sup>

This scenario has been attributed to appendiceal luminal obstruction with associated back pressure effect.<sup>4</sup> Many times, the diagnosis is unclear and it only takes a high index of suspicion coupled with better radiological assessment to unravel this. In this series, the sonography could not help while the CT scan too was equivocal but with endoscopic evaluation, we could make a diagnosis of ascending colon tumor and

#### Corresponding Author:

Dr. Adeyinka A. Adejumo

Department of Surgery (General Surgery), Federal Medical Centre, Keffi, Nassarawa State, Nigeria.

dradejumooa@gmail.com | +2347037700349

DOI: 10.61386/imj.v17i3.525

the patient was thereafter referred to a specialized center for further care.

#### Case summary

AA, a 51 year old male who presented with an insidious onset of right lower abdominal pains with occasional nausea and vomiting. The abdominal

pain has been recurrent over the preceding 3 months before hospital presentation. No history of weight loss but occasional passage of mucoid stool that resolves spontaneously. At the index presentation, there was pain more in the right iliac fossa (RIF), no fever but had nausea and non-bilious vomiting. Clinical examination revealed a middle-aged man, not pale, not dehydrated, afebrile with stable vital signs. There was mild tenderness in RIF although other clinical signs of appendicitis were negative. Total white cell count was 11,000 and no differential neutrophilia. There was mild lymphocytosis and hemoglobin was 11.5g/dl. Abdominal sonography done showed inconclusive report and this prompted the need for computerized tomogram (CT scan). Contrast-enhanced abdomino-pelvic CT scan eventually revealed an apple core deformity in the proximal ascending colon and also features suggestive of appendicitis. Colonoscopy was done and a protruding mass was seen occluding the proximal ascending colon lumen. Multiple biopsies were taken and histopathology eventually reported adenocarcinoma. Baseline carcinoembryonic antigen (CEA) was done and other metastatic work-up. Patient was thereafter referred to oncological center and colorectal surgeon for further care.

## Discussion

The occurrence of caecal or ascending colon tumor co-existing or initiating the process of appendicitis has been earlier reported.<sup>1,5</sup> To the unsuspecting clinician, this diagnosis is usually a dilemma. It has been reported that up to about 25% of caecal tumors are usually heralded by appendicitis.<sup>5</sup> At times, the presentation could be heralded by complicated appendix with rupture and abscess collection hence, the delay in making such a diagnosis because of the staged treatment protocol in this scenario.<sup>6</sup> Usually, the insidious nature of presentation in a patient with RIF pain and other constitutional symptoms like nausea and vomiting in a middle aged patient should make the clinician consider other differential diagnoses of RIF pain. Typically speaking, acute appendicitis will initiate an acute inflammatory process that if not attended to, will lead to serious complications (rupture, abscess, peritonitis) within hours or days necessitating emergency surgery. In some patients, the occurrence of persistent post-appendectomy fecal fistula or sinus while waiting

for an interval appendectomy after drainage of an appendix abscess raises the suspicion of an underlying malignancy.<sup>1</sup>

Laboratory work-up in patients with acute appendicitis usually revealed a complete blood count with leukocytosis and differential neutrophilia.<sup>7</sup> However, in our index patient, the total white cell count was 11,000, differential neutrophil count of 65% but with differential lymphocytosis (42%). All these did not give substantial evidence of an on-going acute inflammatory process. For equivocal situations like this, the use of a simple clinical tool was employed using the modified Alvarado scoring system. A modified Alvarado's score of 4 was obtained in this patient depicting the fact that the diagnosis was unlikely to be acute appendicitis. With all these equivocal clinical and laboratory findings, we were compelled to use radiological modalities to further evaluate the patient.

Abdominal sonography in the evaluation of appendicitis is readily available, cheap though operator-dependent but this modality will demonstrate probe tenderness in the RIF, shows a non-compressible tubular structure located at the caudal end of the caecum with luminal diameter is  $\geq 6$ mm, mural thickening  $\geq 3$ mm, presence of peri-appendiceal fluid and/or fecolith.<sup>8</sup> In our index patient, the appendix couldn't be visualized hence; the need for a contrast-enhanced CT scans. In addition to the establishment of a correct diagnosis, the CT scan has a specificity diagnostic rate of 93-98% for appendicitis and even more so quite useful in obese. The CT scan could also identify associated complications of the appendix (abscess, phlegmon) that may be present as well as revealing other co-existing pathologies around the terminal ileum and ascending colon such as Crohn's disease, Meckel's diverticulitis, caecal diverticulitis, urinary tract stones and retroperitoneal diseases (psoas abscess).<sup>9</sup> The CT scan findings in our patient were also equivocal to some extent with the appendix seen, dilated up to 6.5mm, and presence of air and contrast within the lumen, associated thickening of the caecal wall extending into the ascending colon with an apple core deformity [Figure 1]. The patient subsequently underwent colonoscopy which revealed a protruding mass at ascending colon [Figure 2]. Biopsies were taken for histopathology

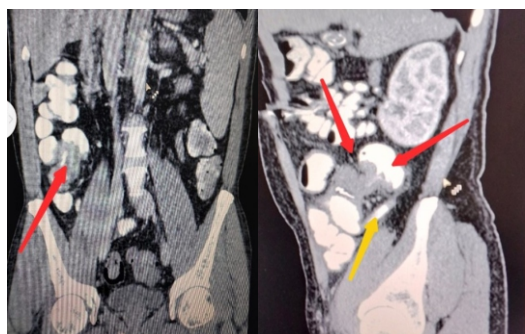


Figure 1: CT scan-Red arrow shows the ascending colon mass demonstrating filling defect (apple core deformity)

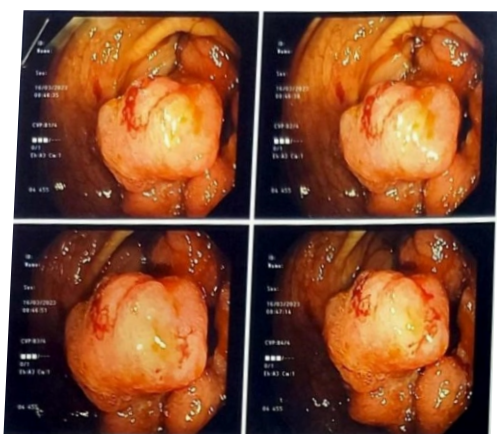


Figure 2: Endoscopic image showing protruding ascending colon mass

which eventually confirmed adenocarcinoma. Retrospectively, this patient had secondary appendicitis from the back pressure effect and attendant appendicular luminal obstruction. This finding has been earlier reported by other workers therefore establishing the relationship between right colon and/or caecal tumor mimicking appendicitis especially in the middle aged when the symptoms and signs do not typically follow the usual pattern expected of appendicitis. In order not to miss the diagnosis of a possible cancer of the caecum or right colon, colonoscopy has been strongly advocated to be done within 6 weeks of appendectomy in patients who are 40 years old and above.<sup>10</sup>

### Conclusion

There is a cause-effect relationship between caecal/ascending colon tumor and appendicitis (secondary appendicitis) therefore; the clinician should bear this in mind when the constellation of the symptoms and signs do not conform to that of

typical pattern that is expected to be seen in appendicitis especially in middle aged patients.

### References

1. Lai HW, Loong CC, Tai LC, Wu CW, Lui WY. Incidence and odds ratio of appendicitis as first manifestation of colon cancer: a retrospective analysis of 1873 patients. *J Gastroenterol Hepatol.* 2006; 21(11):1693-6.
2. Murphy J. Two thousand operations for appendicitis, with deductions from his personal experience. *Am J Med Sci.* 1904; 128: 187-211.
3. Afenigus AD, Bayieh AM, Kassahun B. Treatment outcomes of acute appendicitis and associated factors among admitted patients with a diagnosis of acute abdomen in Debre Markos Referral Hospital, Amhara Region, North West Ethiopia. *J. Periop. Pract.* 2022;32(5):123-130.
4. Kugler N, Patte C, Somberg L, Carver T. Appendicitis Secondary to Caecal Cancer. *Ann Clin Case Rep.* 2019; 4: 1665
5. Shine RJ, Zarifeh A, Frampton C, Rossaak J. Appendicitis presenting as the first manifestation of colorectal carcinoma: a 13-year retrospective study *NZMJ.* 2017; 130 (1459): 26-32.
6. Sanchez AA, Torres EMT, Martinez DC, Pena SR. Colon cancer presenting as appendiceal abscess in a young patient. *Can J Surg.* 2008; 51(1): E15-16.
7. Al-gaithy ZK. Clinical value of total white blood cells and neutrophil counts in patients with suspected appendicitis: retrospective study. *World J. Emerg. Surg.* 2012 7:32. doi:10.1186/1749-7922-7-32
8. Xifara S, Katergianakis V, Vlastarakos P. The role of ultrasound in the diagnosis of acute appendicitis. *Hellenic J Surg.* 2013; 85: 35-41. doi.org/10.1007/s13126-013-0004-x.
9. Rud B, Vejborg TS, Rappeport ED, Reitsma JB, Wille-Jørgensen P. Computed tomography for diagnosis of acute appendicitis in adults. *Cochrane Database Syst Rev.* 2019. 19; 2019(11): CD009977. doi: 10.1002/14651858.CD009977.pub2.
10. Kugler N, Patte C, Somberg L, Carver T. Appendicitis Secondary to Cecal Cancer. *Ann Clin Case Rep.* 2019; 4: 1665.