



## An appraisal of ascitic fluid cytopathology in a Nigerian tertiary care setting

\*Obahiagbon I., \*\*Ugiagbe R.A.

\*Department of Anatomical Pathology, University of Benin Teaching Hospital, Benin City, Edo State.

\*\*Department of Medicine, University of Benin Teaching Hospital, Benin City, Edo State.

### Abstract

**Background:** The pathological accumulation of excess fluid in the peritoneal cavity is termed ascites. It is important to include cytological examination in the overall evaluation of ascitic fluid, so as to help make a distinction between malignant and non-malignant ascites in the management of patients.

**Aims and objectives:** To appraise the practice of ascitic fluid cytopathology in the University of Benin Teaching Hospital (UBTH), Benin City.

**Materials and methods:** Ascitic fluid specimens received at the department of Anatomical Pathology, UBTH, over a 5-year period (2015-2019), were examined macroscopically and centrifuged. Smears were made of the sediments on glass slides and stained with rapid Romanowsky, haematoxylin/eosin and Papanicolaou stains for cytopathological (microscopic) examination by consultant pathologists.

**Results:** A total of 262 ascitic fluid specimens were analysed during the 5-year study period. One hundred and four (39.7%) of the specimens were from males while 158 (60.3%) were from females, giving a male to female ratio of 1:1.5. The age range of the patients was 0.5 – 87years. The mean age was 44.8years. The modal age group was the 40-49 year age group (22.6%). Forty-five (17.2%) smears contained malignant cells, 29 (11.1%) were suspicious for malignancy, 108 (41.2%) were negative for malignant cells, and 80 (30.5%) were unsatisfactory.

**Conclusion:** Ascitic fluid cytopathology remains a relevant modality for the prompt evaluation of patients with clinically detectable ascites in our setting.

**KEYWORDS:** Ascitic fluid, Aspirate, Cytopathology, Benin City.

### Introduction

The parietal and visceral layers of the peritoneum are separated by a thin layer of peritoneal fluid, which is an ultra-filtrate of plasma. The pathological accumulation of excess fluid in the peritoneal cavity, whether by an exudative or a transudative process, is termed ascites.<sup>1</sup> Exudative (protein-rich) ascites results from infections, injuries and malignancies (primary or metastatic) involving the peritoneum, while transudative (protein-poor) ascites results from haemodynamic disturbances resulting in third-space serous fluid

accumulations.<sup>2,3</sup>

Liver cirrhosis has been widely reported as the commonest cause of ascites. Although malignant ascites is much less common, it remains important to include cytological examination in the overall evaluation of ascitic fluid, so as to help make a distinction between malignant and non-malignant ascites in the management of patients.<sup>1,4</sup>

Cytopathological analysis of ascitic fluid has been shown to be a cheap and rapid diagnostic procedure, with the sensitivity, specificity and overall usefulness increasing as expertise increases in specimen collection, specimen handling, transportation, and in the reportage of the smears.<sup>5</sup>

This study sought to appraise the practice of ascitic

**Corresponding Author: Dr Obahiagbon I**

Department of Anatomical Pathology,  
University of Benin Teaching Hospital, Benin City,  
Edo State, Nigeria.

E-mail: ikflex@yahoo.com, Tel: 08059064969

fluid cytopathology in our environment in recent years.

### Materials and methods

Ascitic fluid specimens received at the department of Anatomical Pathology, UBTH, between January 1, 2015 and December 31, 2019 were the materials for this study. They were centrifuged to generate presumably cellular deposits which were smeared on glass slides and immediately fixed in 95% ethyl alcohol before staining with haematoxylin/eosin and Papanicolaou stains, except for the air-dried slides which were fixed in methanol and stained with rapid Romanowsky stain. All the slides were reported by consultant pathologists, with due

consideration of the available patients' clinical information, as "positive for malignant cells", "suspicious for malignancy", "negative for malignant cells" and "unsatisfactory". Smears negative for malignant cells were further categorized as "inflammatory", "reactive mesothelial hyperplasia" and "negative, not otherwise qualified".

Smears reported to be unsatisfactory or inadequate for cytopathological diagnosis were those found to be paucicellular or acellular, those comprising only haemorrhage or those with overwhelming artefacts. The data obtained were analysed using Microsoft Excel and are presented in simple descriptive tables and figures.

**Table 1: Age and sex distribution of the patients**

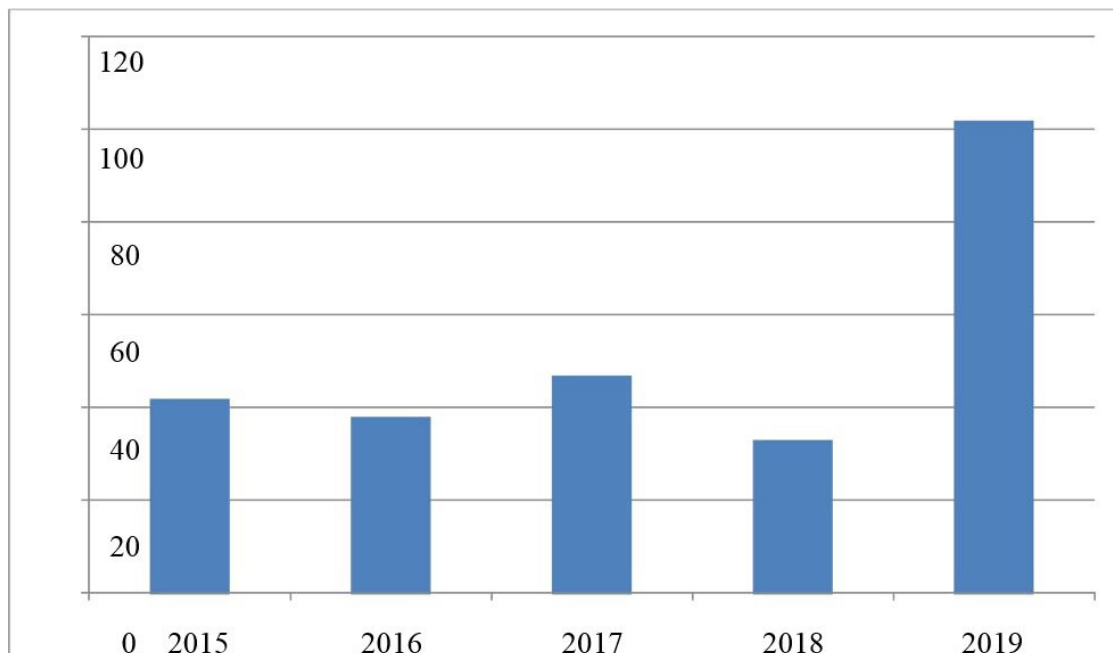
Age groups	Male	Female	Total frequency	Percentages
0-9	2	7	9	3.4
10-19	2	6	8	3.1
20-29	6	21	27	10.3
30-39	15	29	44	16.9
40-49	20	34	54	20.7
50-59	18	16	34	12.7
60-69	24	15	39	14.9
70-79	10	9	19	7.3
80-89	0	5	5	1.9
Age not stated	7	16	23	8.8
<b>TOTAL</b>	<b>104</b>	<b>158</b>	<b>262</b>	<b>100.0</b>

**Table 2: Diagnostic categories of ascitic fluid cytology**

DIAGNOSTIC CATEGORIES	FREQUENCY	PERCENTAGES
POSITIVE FOR MALIGNANT CELLS	45	17.2
Probable primary site stated	(ovary-3, lymphoma-3)	
Probable primary site unknown	(39)	
SUSPICIOUS FOR MALIGNANCY	29	11.1
NEGATIVE FOR MALIGNANT CELLS	108	41.2
Inflammatory smears	(82)	
Reactive mesothelial hyperplasia	(9)	
Negative, not otherwise qualified	(17)	
UNSATISFACTORY	80	30.5
<b>TOTAL</b>	<b>262</b>	<b>100.0</b>

**Table 3: Age and sex distribution of the patients with malignant smears**

Age groups	Gender		Frequency	Percentages
	Male	Female		
0-9	0	1	1	2.2
10-19	0	1	1	2.2
20-29	0	4	4	8.9
30-39	3	4	7	15.5
40-49	5	8	13	28.9
50-59	0	3	3	6.7
60-69	6	6	12	26.7
70-79	2	2	4	8.9
<b>TOTAL</b>	16	29	45	100.0



**Figure 1: Yearly frequency of ascitic fluid cytology**

**Results**

A total of 262 ascitic fluid specimens were examined during the 5-year period of this study. Figure 1 shows a fairly stable yearly frequency for ascitic fluid cytology until 2019 in which more than a third (38.9%) of the specimens were received.

One hundred and four (39.7%) of the specimens were from males while 158 (60.3%) were from females, giving a male to female ratio of 1:1.5. The age range of the patients was 0.5–87years. The

mean age was  $44.8 \pm 18.1$  years. The modal age group was the 40-49 year age group (22.6%) as shown in table 1.

Forty-five (17.2%) smears contained malignant cells, 29(11.1%) were suspicious for malignancy, 108(41.2%) were negative for malignant cells, and 80(30.5%) were unsatisfactory. Of the 108 smears of aspirates that were negative for malignant cells 82(31.3%) were inflammatory, 9(3.4%) showed reactive mesothelial hyperplasia and 17(6.5%) were

negative, not otherwise qualified. These findings are presented in Table 2.

The age range for malignant smears was 7–74 years, with a mean age of 48 years. The modal age group was 40–49 years, closely followed by 60–69 years. Most (64.4%) of the malignant smears were from females, comprising 18.4% of all the samples received from females, while 35.6% of the malignant smears were from males, comprising 15.4% of all the samples received from males, as shown in table 3.

Probable primary sites (ovarian and lymphoid origin) were stated in 13.3% of the cases of malignant smears (Table 2). A diagnosis of carcinoma or adenocarcinoma was made in another 22.2% of the cases of malignant smears, but with no reference to the primary site.

### Discussion

The presence of ascites may be suspected from history and confirmed by physical examination, and about 1500ml of fluid must be present before ascites is detected on abdominal examination.<sup>6</sup> The confirmation of the presence of ascites is based on abdominal paracentesis or detection by imaging studies, with ultrasonography, which can detect as little as 100ml of fluid in the abdomen.<sup>7</sup> Abdominal paracentesis with appropriate ascitic fluid biochemical and cytopathological analysis is probably the most rapid and cost effective method of diagnosing the causes of ascites.<sup>1</sup> The causes of ascites include liver cirrhosis, congestive cardiac failure, intra-abdominal malignancies, chronic renal disease, tuberculosis, bacterial peritonitis and myxoedema.<sup>5</sup> Ascitic fluid cytology is useful in demonstrating the presence or absence of malignant cells and predicting prognosis.<sup>8</sup>

In this study forty-five (17.2%) out of 262 smears contained malignant cells. This percentage is lower than the first two reports from this centre (31.5%<sup>8</sup> and 27.1%<sup>5</sup>), as well as 24.2% reported in Ibadan,<sup>9</sup> but similar to the 17% reported in California, US<sup>10</sup> and higher than 10% reported in Leicester, UK.<sup>11</sup> While the number of cases (262) of ascitic fluid examined is similar to that of a previous study,<sup>5</sup> (277) which was also done at the UBTH over a

period of 5 years, it was higher than an initial study,<sup>8</sup> (235) in the same hospital, done over a period of 10 years. The percentage of smears containing malignant cells on the other hand appears to be on the decline. The reason for this may be the increasing availability and use of imaging studies like computerised tomography, and preference for tissue diagnosis instead of cytology for suspected cases of malignant ascites.

The peak age group for the diagnosis of malignancy via ascitic fluid aspirate cytopathology in this study is the 40–49 year age group. This is similar to the finding of an earlier study done in Benin,<sup>8</sup> as well as that of a study in Nepal.<sup>12</sup>

The results of several studies on ascitic fluid aspirates reveal that the majority of the specimens are received from females and that malignant ascites is also cytologically diagnosed more frequently in females.<sup>5,8,12</sup> This study obtained similar results: 60.3% of the aspirates were received from female patients and 64.4% of the malignant smears were from females.

Unlike in previous decades, currently pathologists may be less likely to state in their reports the primary sites of origin of malignant cells seen in ascitic fluid aspirates. This trend is demonstrable by the declining percentages of our reports containing information about the probable primary sites of malignant cells detected by cytomorphological evaluation of ascitic fluid aspirates. This percentage has dropped sharply from 87.8% in the period spanning from 2002 - 2011,<sup>8</sup> to 24% in the period spanning from 2010 –2014,<sup>5</sup> to 13.3% in the current study period. Of note is the fact that these smears were all reported by essentially the same group of pathologists over these years - older pathologists as well as the younger ones who had come through their tutelage. Furthermore, this tendency to be silent on primary sites may be related to the preference for histopathological examination of tissue biopsy specimens because of greater sensitivity and specificity. Moreover, there is the increasing availability of advanced imaging techniques to localize primary tumours, and also, immunohistochemical and molecular genetic techniques for determining the lineage or

histogenesis of tumours when routine histopathological evaluation proves unreliable. Image-guided fine needle aspiration for cytology of an identified primary site introduces further financial costs to patients, most of whom make out-of-pocket payments. It also raises the requirements for more equipment, expertise and logistics. Immunocytochemical analysis of cytological smears is not readily available. Pathologists are likely to continue to avoid stating the primary sites of origin of malignant cells detected on cytopathological examination of ascitic fluid aspirates for as long as these limitations persist.

As the practice of cytopathology has continued to evolve, it has been recommended that the reporting of smears as “atypical cells” or “suspicious for malignancy” ought to be not more than 5% of cases, including by examination of multiple specimens from a given patient with a view to categorizing the smears as either positive or negative for malignant cells.<sup>13</sup> In the index study period 29 (11.1%) were suspicious for malignancy, which represents a slight improvement from the 12.3% recorded in the previous study from this centre.<sup>5</sup>

Eighty (30.5%) aspirates were either acellular, or in other respects unsuitable for cytopathological diagnosis, and as such were categorized as unsatisfactory. This is a similar proportion to that of the previous study from here.<sup>5</sup> Ascites due to haemodynamic disorders is likely to yield acellular smears, and such specimens are inadequate for cytopathological diagnoses. Biochemical evaluation rather than cytopathological is recommended for such cases;<sup>1,10,11</sup> but when such specimens are nevertheless sent to the cytopathology laboratory, they end up being analysed cytopathologically with the eventual categorization as unsatisfactory. The proportion of unsatisfactory smears may also be increased by delays in the transportation of specimens to the laboratory following collection, and/or by delays in processing the specimens once received at the laboratory. The implication of such delays is that potentially diagnostic cells are liable to degenerative changes that adversely affect the diagnosis.

### Limitation of the study

The study was limited by the lack of facilities for immunocytochemical confirmation of suspected cases of malignant ascites.

In conclusion, ascitic fluid cytopathology continues to have its place as a rapid, useful and affordable modality in the evaluation of patients with ascites in our setting. This fact is reflected in the steady rate of requests by clinicians over the last decade. It costs patients only N2,500 in our centre as at the time of writing, and the turnaround time is often as short as 24 hours. Its potential can however be maximized by a careful and informed selection of suitable patients, proper and adequate specimen collection, prompt transportation and processing, and good clinico-pathological correlation. In addition, immunocytochemistry should be made readily available to routinely aid the localization of primary sites in cases of malignant ascites. There remains room for improvement in the technical skills of the cytotechnicians and the diagnostic acumen of the cytopathologists.

### References:

1. Tarn AC, Lapworth R. Biochemical analysis of ascitic (peritoneal) fluid: what should we measure? *Annals of Clinical Biochemistry* 2010; 47:397-407.
2. Tasneem H, Shahbaz H, Sherazi BA. Causes, management and complications of ascites: a review. *International Current Pharmaceutical Journal* 2015; 4:370-7.
3. John S, Friedman LS. Portal Hypertensive Ascites: Current Status. *Current Hepatology Reports* 2020; 24:1-9.
4. Ekpe EL, Omotoso AJ. The sensitivity of cytology in the differential diagnosis of ascites among adult Nigerians in a Tertiary Health Institution. *Sch J Appl Med Sci*. 2015; 3:969-72.
5. Udoh MO, Ugiagbe EE. Pattern of ascitic fluid cytology in a tertiary centre: a 5 year review. *Annals of Biomedical Sciences*. 2016; 15:134-40.
6. Cattau EL, Benjamin SB, Knuff TE, Castell DO. The accuracy of the physical examination in the diagnosis of suspected ascites. *JAMA* 1982; 247:1164-6.

7. Runyon BA. Management of adult patients with ascites caused by cirrhosis. *Hepatology* 2004; 39:841.
8. Nwafor CC, Forae GD. Cytological diagnosis of ascitic fluid in Benin City, Nigeria. *Nig Qt. J. Hosp. Med.* 2014; 24:46-50.
9. Junaid JA, Odor EIA. Cytologic diagnosis of ascitic fluid in Ibadan, Nigeria. *Journal of the National medical Association* 1980; 72:669-72.
10. Runyon BA, Hoefs JC, Morgan TR. Ascitic fluid analysis in malignancy related ascites. *Hepatology* 1988; 8:1104-9.
11. Karoo RO, Lloyd TD, Garcea G, Redway HD, Robertson GS. How valuable is ascitic cytology in the detection and management of malignancy? *Postgrad Med J* 2003; 79:292-4.
12. Jha R, Shrestha HG, Sayami G, Pradhan SB. Study of effusion cytology in patients with simultaneous malignancy and ascites. *Kathmandu University Medical Journal* 2006; 4:483-7.
13. Cibas ES. Pleural, pericardial, and peritoneal fluids. In: Cibas ES, Ducatman BS(eds). *Cytology: Diagnostic Principles and Clinical Correlates*. Philadelphia, PA: Saunders Elsevier 2009 pp 129-53.