



## The use of pectoral nerves block in the management of post mastectomy pain: Case series

Hanson Osazuwa Idehen, Osayomwanbo Osaheni, Omajuwa Urowoli Dawodu

*Department of Anaesthesiology, University of Benin Teaching Hospital, Benin City, Edo State, Nigeria.*

### Abstract

Pectoral nerve block is novel superficial thoracic wall block, which is an ultrasound guided interfascial plane block. It has many advantages over the use of systemic analgesic, particularly the use of opioids which has various side effects. Numerous studies have shown the analgesic potential of Pectoral nerve block (PEC2) in breast augmentation surgery, small breast surgery and breast cancer surgery. However, there is paucity of such similar studies in the West African sub-Saharan. This case series further highlight the usefulness of PEC block in the management of post mastectomy pains.

**Key Words:** Pectoral Nerve Block, Post Mastectomy Pains

### Introduction

Mastectomy is a surgical procedure commonly performed by the general surgeons. However, in some climes, it may be carried out by gynaecologists. Radical mastectomy is a surgical procedure involving the removal of breast, underlying chest muscle (including pectoralis major and pectoralis minor), and lymph nodes of the axilla as a treatment for breast cancer. While modified radical mastectomy entails either the surgical removal of the whole breast tissue and axillary clearance while sparing the pectoralis major and minor. The commonest indication for mastectomy in our center is metastatic disease of the breast. Like in most other surgeries, acute post-surgical pain commonly exists after breast cancer surgery. Patients who had breast cancer surgery frequently experience clinically meaningful pain with numerical rating score (NRS) greater or equal to 5.<sup>1</sup> There are different options in the management of post mastectomy pain. A combination of analgesics including NSAIDS, gabapentin, pregabalin, alpha 2-adrenergic agonist (clonidine,

dexmedetomidine) but not limited to opioids, wound infiltration, thoracic epidural and paravertebral blocks and recently, the use interfascial plane blocks (PEC 2, Serratus anterior plane block and erector spinae block). The choice of analgesic modality does affect the post-surgical comorbidity which includes inadequate quality of recovery after surgery, persistent post-surgical pain or cancer recurrence during the chronic phase.<sup>2</sup>

In this report we described our experience with Pectoral nerve 2 block for post mastectomy analgesia in patients with breast cancer billed for modified radical mastectomy. It is expected that this would engender an increased interest in the use of this novel, simple and highly effective regional analgesic technique in our sub region.

### Materials and methods

A detailed preoperative assessment was carried out which includes detailed history, examination (general and systemic) and investigations (full blood count, urinalysis, electrolyte and Urea, fasting blood sugar, chest X-ray, electrocardiography, and echocardiography) and Patient was counselled on how to grade pain using the numerical pain scoring system.

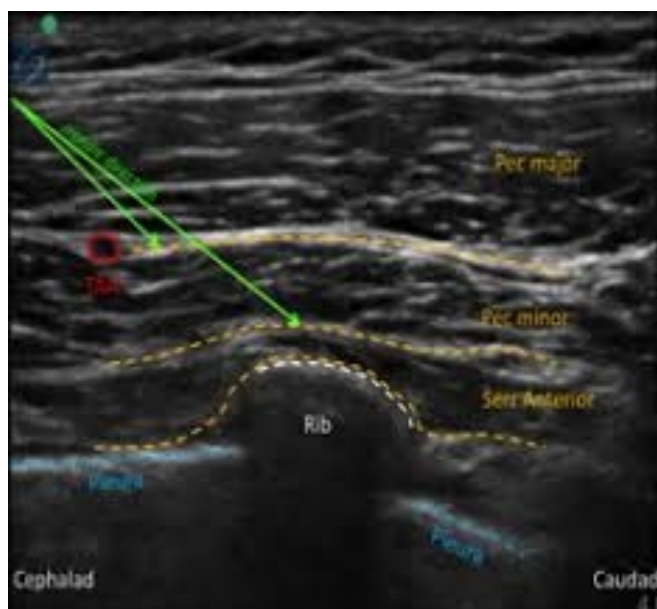
In the theatre patient multi-parameter attached and baseline vital signs were taken and vascular access sited using a 16G cannula. Pectoral nerve block 11

**Corresponding Author: Dr. Idehen HO**

*Department of Anaesthesiology,  
University of Benin Teaching Hospital,  
Benin City, Edo State, Nigeria.*

*E-mail: idehenhanson@yahoo.com, Phone: +2348033850091*

was then performed for the provision of intra and post-operative analgesia. This was done using ultrasound guidance (*SonoAceR3 Ultrasound Machine from Samsung, USA*). With patient positioned supine, the anterior chest wall cleaned. Under strict asepsis, a high frequency linear ultrasound probe was placed on the hemi thorax. Starting from mid-clavicular point, with the identification of the axillary artery and vein, the was moved laterally and caudally till the fascial plane between pectoralis minor and serratus anterior muscle was identified over the 4th rib. PECS 2 block was performed by injecting 20ml of 0.25 % plain bupivacaine using 100mm length of 25G stimuplex needle (*B Braun*) into this plane with the 4th rib preventing pleural puncture and avoiding a pneumothorax. Thereafter, the needle was then withdrawn superficially to lie in a plane between the pectoralis major and minor at the 3rd rib and 10 ml of the same solution was deposited. Identification of the pectoral branch of the thoraco-acromium artery maybe seen at this level (PECS 1 block). Block assessment was done 15 minutes after deposition of LA, the patients was noticed to have a reduction in pinprick sensation in T2-T5 dermatomes on the chest wall relative to the contralateral side if successfully performed.



*Illustration of PEC 2 block*

General anaesthesia was induced using sleep dose of propofol and 1.5mg/kg of suxamethonium was used to facilitate laryngoscopy and tracheal intubation using appropriate sized cuffed tube. Anaesthesia was maintained with one MAC of isoflurane in oxygen at 4l/min or the use of TIVA. Intraoperative multimodal analgesia and muscle relaxant administered. At the end of surgery residual neuromuscular effect was antagonized. Duration of surgery, blood loss, and urine output noted. In the immediate post operative period, NRS Pain score assessed every 30 minutes. Whenever the NRS score was greater than 3, systemic analgesics was administered intramuscularly and were given at scheduled times for 48 hours.

#### Case 1

A.P, a 52-year-old female trader who presented with a two-year history of right breast mass which has been progressively increasing in size, there was no history suggestive of metastasis. However, the breast had Peaud'orange with nipple retraction with a nodular mass with ill-defined edges measuring 12 by 18 centimeters and firm in consistency. There was no nipple discharge or palpable axillary lymph nodes. Histology report revealed an invasive right breast carcinoma. Patient had Doxetaxel and Capecitabine as neoadjuvant chemotherapy. A known diabetic patient of seven years duration on oral hypoglycemic medications (metformin and glibenclamide).

Examination revealed a clinically stable middle-aged lady scheduled for modified radical mastectomy. Preoperative Laboratory investigations (full blood count, urinalysis and electrolyte and urea) were within normal values. However, random blood sugar was 264 mg/dl while fasting blood sugar was 179mg/dl. Chest x-ray showed cardiomegaly, electrocardiogram revealed a sinus rhythm and echocardiography revealed aortic root dilatation, mild aortic regurgitation and ejection fraction of 76.9%.

At the end of surgery which lasted 2hrs, Pain score immediately following emergence from anaesthesia (NRS) was 0/10 and remained so till the 10th post-operative hour when the pain was graded 4/10. This necessitated the commencement of systemic analgesics (Intravenous tramadol 100mg 8 hourly, intramuscular diclofenac 75 mg 12 hourly and

paracetamol 600mg 8hourly) were administered intramuscularly and were given at scheduled times for 48 hours.

#### Case 2

W.E, a 40-year-old hair stylist who presented with a 2 months history of a progressively increasing right cystic breast swelling. There was no associated skin redness, skin change, nipple retraction, deviation or destruction. There was also no history suggestive of metastases.

Examination revealed a healthy middle-aged lady. General examination was essentially normal. A diagnosis of hypertensive heart disease was made by the cardiologist because of elevated blood pressure and placed was on 5mg of Amlodipine daily. An assessment of a low post operative cardiovascular risk for surgery was made.

Due to the inflammatory nature of the mass, a preoperative incision of the cystic mass was done and 20 ml of serosanguinous effluent was drained and oral antibiotics were administered. Excision biopsy was suggestive of medullary breast carcinoma. Patient then received neoadjuvant chemotherapy before scheduling her for a right modified radical mastectomy.

Preoperative Laboratory workup were within normal range of values except hypokalaemia of 3.1 mmmol/litre necessitating pre-operative optimization. Patient was counselled on how to grade pain using the numerical pain scoring system. Surgery lasted 2 hours 45 minutes, following emergence from anaesthesia and transfer to PACU, pain score was 1/10 and remained so during the hourly pain assessment despite not receiving additional systemic analgesics. At the 17<sup>th</sup> post-operative hour, her pain score increased to 4/ 10 hence systemic analgesics (100mg tramadol, 75 mg diclofenac and 900mg paracetamol) were administered. They were given at scheduled times for the subsequent 48 hours. Oral analgesics were then employed thereafter for 5 days on the surgical ward.

#### Case 3

E.O, a 41-year-old female trader who presented with a 4-month history of a right breast swelling. Her referral letter and mammogram suggest a mitotic breast lesion but there was no history of

weight loss, anorexia or bone pain. Examination revealed breast asymmetry with an obvious right breast swelling with associated yellowish nipple discharge. The right breast had a 6cm by 6cm mass which was hard in consistency but painless. There was an incidental finding of a 2cm by 2cm mass in the left breast. There was no associated nipple discharge in the left breast.

An assessment of bilateral Mitotic disease of the breast was made. Biopsies of both breast revealed an invasive carcinoma of the right breast while the left had a non- malignant disease (mammary duct ectasia). Patient had complete course of intravenous chemotherapy comprising Docitaxel, Epirubicin and cyclophosphamide prior to scheduling for modified Radical mastectomy of the right breast.

Pre- operative investigations were within normal limits. Chest x-ray revealed no abnormal findings and electrocardiogram done revealed a sinus heart rhythm. Patient was counselled on how to grade pain using the numerical pain scoring system.

Surgery lasted 2 hours and 10minutes, following emergence from anaesthesia, NRS pain score was 2/10. At the 5<sup>th</sup> post-operative hour, patient complained of discomfort at the surgical site but her pain score remained 2/10. At the 15<sup>th</sup> hour post operatively, the score increased to 4/10 necessitating the commencement of intramuscular systemic analgesics (diclofenac 75mg 12hourly, paracetamol 600mg 8hourly and tramadol 100mg8hourly).

#### Case 4

A 37-year-old male driver with 8 months history of a right breast lump. It was initially small and progressively increased in size. Incisional biopsy done revealed invasive lobular carcinoma and chest X-ray showed multiple small nodules in keeping with pulmonary metastasis. An assessment of advanced Carcinoma was made and was commenced on neo-adjuvant chemotherapy using intravenous Docetaxel and Tabs capacitabine. He however had 4 courses of chemotherapy before he was scheduled for simple mastectomy.

Preoperative assessment had no co-morbidities or significant medical history. General Physical examination was essentially normal. His pulse rate was 86 beats per minute, blood pressure was 120/90 mmHg, respiratory rate was 14 cycles per minute,

breathe sounds were vesicular. Other system examinations were normal. Preoperative laboratory investigations were within normal limits. An assessment of ASA I was made and he was counseled for a general anaesthesia technique with PECS 11 block for intra and post-operative analgesia and he was schooled on how to grade pain using the numerical pain scoring system.

Immediate post-operative Numerical rating scale pain score was 2/10. Patient experienced continuous analgesia and paraesthesia over the mastectomy site on the right hemi thorax for 24 hours.

### Discussion

This case series demonstrated the effectiveness of pectoral nerve block (PEC 11) in the management of post mastectomy pains just as Jia and colleagues revealed in a meta-analysis of randomized control trials.<sup>3</sup> Its utilization led to prolonged time to first analgesic request, less use of post-operative analgesic (opioids). The use of opioids have been implicated in cancer recurrence,<sup>4,5</sup> lower pain scores compared to those that didn't have it.

The average duration of pain relief in this series was about 16.5 hours (10, 17, 15, 24hrs). Of note in the 4<sup>th</sup> case, the male patient had the longest duration of pain free period, possibly because of less tissue desiccation considering the size of the male breast. Pain free period of 16.5 hour is longer than the average of 6-8hrs reported by Mary et al,<sup>6</sup> they speculated that this discrepancy could be as a result of the time of administration of their PEC block, which was administered preoperatively. However, we established our blocks preoperatively, this undermines timing of the PEC block as a reason for the reduced duration of block. The reason for this prolonged pain free period could be due to the type of LA used. Bupivacaine has a longer duration when compared to ropivacaine which might be responsible for the prolonged duration. Prolonged period of analgesia up to 7days have been documented.<sup>7</sup>

The innervation of the breast is supplied mainly by the medial and lateral branches of the 2<sup>nd</sup> to the 6<sup>th</sup> intercostal nerves, which arise from the thoracic spinal nerves (T2-T6).<sup>7</sup> The apex of the axilla is supplied by the intercosto-brachialis nerve, which is a cutaneous branch of the second intercostal nerve while the medial brachial cutaneous nerve supplies

the superior part of the axilla. The long thoracic nerve supplies the serratus anterior muscle (C5-C7). The thoracodorsal nerve (C6-C8) supplies latissimus dorsi that is relevant in more extensive procedure. The superior part of the anterior chest wall is supplied by the supraclavicular nerve which is derived from the cervical plexus. Simple mastectomy for breast conservation surgery entails the blockade of the pectoral and lateral branches of the intercostal nerves. However, more extensive surgery like modified radical mastectomy may require the blockade of all the above-mentioned nerves.

PEC 1 and PEC 11 block are inter-fascial superficial blocks of the thoracic wall, which blocks the pectoral and intercostal nerves. It can be used to provide analgesia for breast surgery and other procedures/surgery involving the anterior chest wall. However, to provide complete/adequate analgesia for modified radical mastectomy there will be need to block the medial and lateral cutaneous branches of the 2<sup>nd</sup>-6<sup>th</sup> intercostal nerves, medial cutaneous nerve of arm, lateral and medial pectoral nerves, long thoracic nerve, thoraco-dorsal nerve and supraclavicular nerves. Although some authorities are of the view that supraclavicular nerve block is not too important for post mastectomy pain management because the surgical incision does not extend that high to involve those groups of nerves. More extensive procedure may require blockade of the supraclavicular nerves or a serratus anterior plane block. Nevertheless, others argue that PEC blocks do not block the medial/anterior cutaneous branches of the 2<sup>nd</sup> to 6<sup>th</sup> intercostal nerves. This can be achieved by infiltrating the medial edge of the sternum in order to block the anterior branches. While some think combining transversus thoracic muscle plane block and pectoral nerve block provides more effective perioperative pain relief than pectoral nerve block alone for cancer surgery,<sup>9</sup> parasternal intercostal nerve (PSI) block has been reported as an alternative.<sup>10</sup>

There are other analgesic options in the perioperative management of post mastectomy pain, this includes thoracic epidural, thoracic paravertebral block, intercostal nerve block. The gold standard for the management of post mastectomy pain was thoracic epidural. With surgical techniques becoming less invasive, the

introduction of enhanced recovery pathways, and the increased use of anticoagulation therapies, the use of epidural anaesthesia has decreased among many clinical practitioners.<sup>11</sup> However, it is associated with complications such as intrathecal spread, nerve damage, epidural haematoma, inadvertent intravascular deposition of LA.<sup>12</sup> Thoracic paravertebral block which is an alternative to the thoracic epidural, nevertheless they have similar complications. Both are associated with a high failure rate of about 15%.<sup>13</sup>

Interfacial plane blocks are options for post mastectomy pain management, amongst them are the PECS, Serratus Anterior Plane (SAP) and Erector Spinae Plane (ESP) blocks. However, ESP block has shown promise as a regional technique for breast surgery analgesia. Some studies showed that it has effective analgesia effect with a reduced postoperative opioid consumption when compared with standard care in patients undergoing surgery for breast cancer (including mastectomy).<sup>14,15</sup>

Despite this effect, Chandri and coworker found that Pec 11 block was more effective when compared to erector spinae block (ESP) in patients undergoing modified radical mastectomy in terms of postoperative analgesia and opioid consumption.

The concentration of LA used in PEC block is 0.25% bupivacaine (analgesic dose). The prospect of using PEC block as a sole anaesthetic agent is optimistic, considering the fact that 30ml of 0.5% bupivacaine wouldn't have exceeded the maximum safe dose. However, there is paucity of literature on this.

In these series there were some limitations to the use of PEC block in the perioperative pain management of mastectomy. There is the possibility of an advanced malignancy obliterating the sonoatomy making anatomical plane difficult to delineate. Secondly, the possibility of increased serum concentration of LA because of increased vascularization of the tissue in breast cancer,<sup>16</sup> which might manifest as signs of LA toxicity.

### Conclusion

Pectoral nerve block is an effective and novel regional technique which should be part of the anesthesiologists' armamentarium for a comprehensive anaesthesia regimen in our sub region.

### References:

1. Okamoto A, Yamasaki M, Yokota I, Mori M, Matsuda M, Yamaguchi Y et al. Classification of acute pain trajectory after breast cancer surgery identifies parent's at risk for persistent pains: A prospective observational study. *Journal of pain research* 2018; 11:2197-2206.
2. Fuminosa A, Toyoshi H, Akiko O, Magumi M, Yosuke Y, Shunsuke Y et al. Can acute pain treatment reduce post-surgical co-morbidity after breast cancer surgery? A literature review. *Bio RES Int* 2015;641508. Doi: 1155/2015/641508.
3. Jia Z, Fanglei H, Yang Y. Pectoral nerve block in anaesthesia for modified radical mastectomy: A meta-analysis based on randomized control trials. *Medicine* 2019; 98: e15423. Doi:10.1097/MD.00000000000015423.
4. Divtia JV, Ambulkar R. Anaesthesia and cancer recurrence. What is the evidence? *J Anaesthesiol Clin Pharmacol* 2014; 30:147-150.
5. Lin X, Wang YJ, Li Q, Hou YY, Hong MH, Cao YL, et al. Chronic high dose morphine treatment promotes SH-SY5Y cell apoptosis via c-Jun N terminal kinase mediated activation of mitochondrial dependent pathway. *FEBS J* 2009; 276:2022-2036.
6. Mary T, Frenny A P, Arun PM, KM Jagathnath Krishna. Intraoperative pectoral nerve block (Pec) for breast cancer surgery: A randomized controlled trial. *J of Anaesthesiology Clin Pharmacol*. 2018; 34:318-323.
7. Wijayasinghe N, Anderson KG, Kehlet H. Analgesic and sensory effects of the Pecs local anaesthetic block in patients with persistent pain after breast cancer surgery: A pilot study. *Pain Pract* 2017; 17:185-191.
8. Sarhadi NS, Shaw Dann J, Lee FD, Soutar DS. Anatomical study of the nerve supply of the breast, including the nipple and areolar. *Br J Plast Surg* 1996; 49: 156-164.
9. Ueshima H, Otake H. Addition of transversus thoracic muscle plane block to pectoral nerves block provides more effective perioperative pain relief than pectoral nerves block alone for breast cancer surgery. *BJA* 2017; 118:439-443.
10. Hironobu H, Hiroshi O, Eiko H, Rafael B. How

- to use pectoral nerve block effectively- An evidence based update. *Asaian journal of anaesthesiology* 2019; 57:28-36. Doi:10.6859/aja.201906\_57(2).0002.
11. Araz P, Madan N, Arun V. Erector spinae plane block. A review of current evidence. *ATOTW* 414. ([www.wfsahg.org/resources/anaesthesia-tutorial-of-the-week](http://www.wfsahg.org/resources/anaesthesia-tutorial-of-the-week)).
  12. Lynch EP, Welch KJ, Carabuena JM, Eberlein TJ. Thoracic epidural improves outcome after breast surgery, *Annals of surgery*, 1995; 22:663-669
  13. Romero A, Garcia JEL, Joshi GP. The state of the art in preventing post-thoracotomy pain. *Semin Thorac CardiovascSurg.* 2013; 25:116-124.
  14. G'urkan Y, Aksu C, KusA, Y'or'uko ğlu UH, Kılıç CT. Ultrasound guided erector spinae plane block reduces postoperativeopioid consumption following breast surgery: a randomized controlled study. *J Clin Anesth.* 2018; 50:65-68
  15. Altıparmak B, Korkmaz Toker M, Uysal AI, G'üm'usDemirbilek S. Comparison of the efficacy of erector spinae plane block performed with different concentrations of bupivacaine on postoperative analgesia after mastectomy surgery: randomized, prospective, double blinded trial. *BMC Anesthesiol.* 2019; 19(1):31.
  16. Emilo B-G, Julie KN, Chris cw, Chad RF, James WS. Vascular endothelial growth factor secretion by tumor-infiltrating macrophages essentially support tumor angiogenesis and IgG immune-complex potentiate the process. *Cancer research* 2002; 62: 7042-7049.