



Inadvertent drug plastic foil aspiration mimicking status asthmaticus

Nwafor CC¹, Onwuka CO², Keshinro SO³, Kudamnya IJ¹, Okafor CI²

¹Department of Pathology, University of Uyo, Uyo, Akwa Ibom State

²Department of Histopathology, University of Uyo Teaching Hospital, Uyo, Akwa Ibom State

³Force Pathologist Office, Nigeria Police Force Ikoyi, Lagos

Abstract

Background: Violent asphyxia is mechanical obstruction, resulting in generalized hypoxia, and can result in death of the victim.

Case report: A 28-year-old non-asthmatic male presented with a day history of difficulty in breathing. He also had a history of aspiration of some unknown drugs (one of them together with the plastic foil) two weeks prior to presentation. On the second day of admission, he became restless, slumped and died. A post mortem examination showed a drug plastic foil impacted in a lacerated infraglottic portion of the larynx. The cause of death was concluded as violent asphyxia (choking), due to drug plastic foil impaction.

Conclusion: In addition to the numerous list of materials that can cause FBI is drug plastic foil. If not removed on time causes impaction and laryngeal laceration, laryngeal spasms, laryngotracheobronchitis, vagal inhibition asphyxia and death.

Keywords: Foreign body impaction, FBI, drug plastic foil, laryngeal laceration, laryngeal spasms, laryngotracheobronchitis, vagal inhibition asphyxia, violent asphyxia

Introduction

Violent asphyxia occurs in situations when the airway is mechanically obstructed, thereby leading to generalized hypoxia, and can be fatal. It is also known as mechanical asphyxia.¹ The pathways of the respiratory blockade include compression/constriction of the neck (as seen in hanging, strangulation and throttling), blocking of external orifices of respiration (as seen in smothering, overlying, suffocation, gagging, etc), compression and mechanical fixation of the chest and abdomen preventing respiratory movements (as in crush asphyxia), inhalation of fluid into the respiratory tract (as in drowning) and impaction of foreign body in the respiratory track (as seen in choking).¹⁻⁵ Fatality due to foreign body impaction (FBI) is common in children, epileptics during attacks, and persons with suppressed gag reflex (either due to gross alcohol intoxication or persons on heavy doses of tranquilizers in health institutions or due to substance abuse).¹⁻⁵ Without immediate and successful intervention, high mortality is associated with FBI.

Corresponding Author:

Dr Nwafor Chukwuemeka Charles

Department of Pathology, University of Uyo, Uyo, Akwa Ibom State, Nigeria

nwaforcharles@gmail.edu.ng | +234(0)8102462487

DOI: 10.61386/imj.v17i3.529

Case presentation

A 28-year-old male presented to a health facility with a one-day history of difficulty in breathing. He was not a known asthmatic. He was reviewed by the medical team on call and a history of ingestion of some unknown drugs (one of them together with the plastic foil) which he purchased over the counter for

the treatment of fever and headache 2 weeks prior to presentation was obtained. Radiological investigations were requested to help direct the next line of action. These were not done. On the second day on admission, he became restive and started destroying objects around him and hospital security guards were invited to restrain him. Immediately he was held, he slumped and died. A post mortem examination was performed and the following were the major findings: a drug plastic foil impacted in a lacerated mid portion of the larynx, laryngotracheobronchitis, bronchopneumonia with moderate edema, haemorrhagic gastritis and acute tubular necrosis of the kidneys. See figures 1-4. Petechial haemorrhages on the surface of internal organs were not seen. The cause of death was concluded as violent asphyxia (choking), due to drug plastic foil impaction.

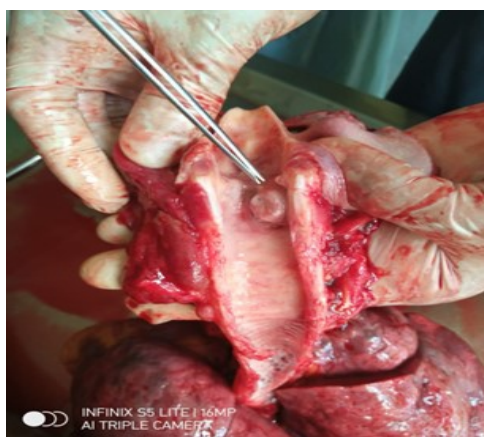

Figure 1: A drug foil lodged in the infraglottis region

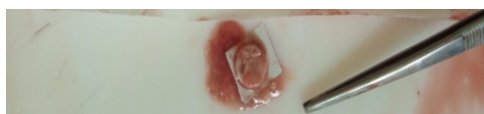


Figure 2: The drug foil

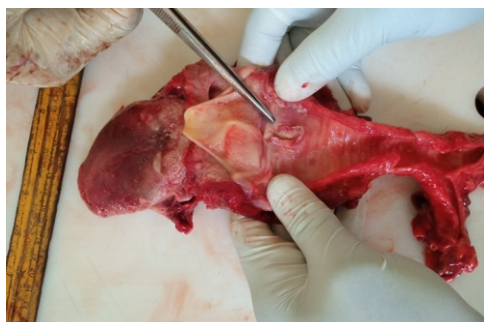

Figure 3: Deep laceration of the infraglottic area

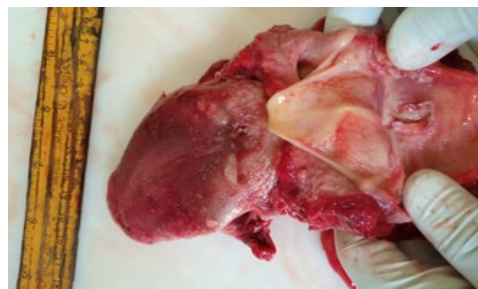

Figure 4: Deep laceration of the infraglottic area

Discussion

Various substances have been reported in literature to cause difficulty in breathing leading to death, following their impaction in various parts of the upper respiratory pathway. These substances could be endogenous (like the tongue in epileptics) or exogenous substances. Exogenous substances which are more common range from edible substances (fruit seeds, bolus of rice particles, meatball, fish or animal bone, spherical solid sweets, candies and toffees) to non edible substances like (metallic coin, piece of balloon and handkerchief stuffed into the mouth).¹⁻⁵ In the index case a plastic drug foil was seen. This has not been reported previously to the best of our knowledge.

The common sites in airway obstruction which can lead to death are the nostrils, back of the mouth, larynx (as seen in the index case), the pharynx, upper part of the trachea and the bronchioles. The commonest site being the larynx.^{2,4} Following the presence of any substance in the airway, it normally induces intense coughing, which aims to clear the airway. Failure of clearance precipitates choking. In FBI on the upper airway, the symptoms are non-specific. The typical symptoms of upper airway obstruction like stridor, respiratory distress, coughing etc are not present.⁴ In café coronary (sudden collapse of healthy subjects during meals), patients manifest with sudden collapse followed by death.⁴ It is often confused with myocardial infarction, due to absence of any sign of asphyxia, respiratory distress or neurological symptoms. The main cause of death is due to reflex vagal inhibition of the heart.⁴

In most cases substances in the airway, block the airway and lead to death by one of these 3 mechanisms (asphyxia, vagal inhibition or laryngeal spasm). Studies have shown that in choking death, the airway blockage does not need to

be complete. Even objects smaller than the airways can elicit fatal laryngospasms. Usually FBI is not associated with obvious injuries in the airway.^{1,2,4} In the index case, the drug plastic foil was seen in the mid portion of larynx and the airway was not completely blocked but deeply lacerated and elicited a serious local inflammatory reaction. The most common site of impaction of foreign bodies in the upper airway is the carina.^{7,8} However newer studies with larger sample sizes have documented that the combined infra and supraglottic position is the commonest site of impaction, especially in cases of café coronary.²

The time interval between FBI, respiratory distress and death is not certain. On the average, fatality occurs following FBI within a few minutes especially in café coronary cases, while in other cases it may last up to few hours.^{2-5,7,8} Determinants of fatality include: size of foreign body aspirated, its texture, its nature, its degradability and the component materials, used in making them. Biodegradable materials of large size can cause rapid fatality due to their ability to cause occlusion. Also non-biodegradable materials that are of large size tends to cause more fatality.¹ In the index case, it was a drug plastic foil (non-degradable), had 4 sharp edges and was of moderate size (2x2x1cm) which increased its ability to cause damage. The long interval between aspiration and impaction may have contributed to the severity of the injury.

Other common autopsy findings in FBI are facial and internal organs congestion, petechial haemorrhages and emphysema of the lungs.^{1-5,7} Pulmonary edema and organ congestion were seen in the index case. Petechial haemorrhage was not seen. This may be because the death of the index case did not occur immediately after the aspiration. Based on manner of death classification, deaths by FBI are usually accidental, though homicidal deaths by this mechanism has been seen when kidnapped/hostage individuals were prevented from talking or shouting by the use of a handkerchief that was stuffed into the mouth. The continuous salivation by the individual, wets the handkerchief and this later choked the individuals. The manner of death of the index case was accidental, though his mental status was not evaluated to know why such a grave mistake was made.

The limitations of this report are lack of assessment of the mental state of the patient and lack of toxicological evaluation, which may have revealed more information.

Conclusion

In addition to the numerous list of materials that can cause FBI is drug plastic foil, which if not removed on time, not only causes impaction and laryngeal laceration, but may also cause laryngeal spasms, laryngotracheobronchitis, vagal inhibition asphyxia and death.

References

1. Rao NG. Violent asphyxia death. In: Rao NG, editor. Textbook of Forensic Medicine and Toxicology. 2nd ed. New Delhi: Jaypee, India 2010. p. 194-220.
2. Regula W, John DG, Roger B. Café coronary syndrome-fatal choking on food: an autopsy approach. J Clin Foren Med 2006; 13 (3): 135-138.
3. Angelo M, Monica S, Alessandro F, Alessio A, Nunzio DN, Filomena C, et al. Risk management and recommendations for the prevention of fatal foreign body aspiration: four cases aged 1.5 to 3 years and mini-review of the literature. Int. J. Environ. Res. Public Health 2020, 17, 4700; doi:10.3390/ijerph17134700.
4. Dhiab MB, Jdidi M, Mansour NB, Souguir MK. Fatal meat aspiration: A report of three cases and review of the literature. Journal of Clinical Pathology and Forensic Medicine 2012; 3 (2): pp. 12-16.
5. Edirisinghe PAS. A café coronary death due to a 'banana'. Sri Lanka J. Forensic Med. Sci. Law 2010; 1(1):22-24.
6. Ette VF. Pattern of ear, nose and throat foreign bodies seen in Uyo Nigeria. Ibom Med J 2006; 1 (1): 10-12.
7. Suleyman G, Fuat G, Yasar T, Ziya K, Kemalettin A. Foreign Body Asphyxiation in Children. Indian Pediatrics 2005; 42: 1131-1133.
8. Yıldız, A. Killing beans; Two cases of asphyxia due to bean seed aspiration. SDU Journal of Health Science Institute/SDÜ Sağlık Bilimleri Enstitüsü Dergisi 2017; 8(3), 78-80.