



## Investigating the effect of selected antiretroviral therapies on serum testosterone and testicular microstructure of Wistar rats

Innocent A. Edagha<sup>1</sup>, Victor A. Umoh<sup>2</sup>, Aniekan I. Peter<sup>1</sup>, Ikanna E. Asuquo<sup>1</sup>, Enobong Udofot<sup>3</sup>, Kenneth E. Archibong<sup>1</sup>

<sup>1</sup>Department of Human Anatomy, Faculty of Basic Medical Sciences, University of Uyo, Nigeria

<sup>2</sup>Department of Internal Medicine, Faculty of Clinical Sciences, University of Uyo Teaching Hospital, Nigeria

<sup>3</sup>Department of Biochemistry, Faculty of Sciences, University of Uyo, Nigeria

### Abstract

**Background:** Highly active antiretroviral therapies (HAARTs) and other antiretroviral therapies (ARTs) are widely used in the management of human immunodeficiency virus/acquired immune deficiency syndrome (HIV/AIDS) as well as repurposing for other infectious conditions despite their reported toxicities. We investigated the gonado-toxicities of two HAARTs and five ARTs *in vivo* model.

**Materials and methods:** Forty adult male Wistar rats were allotted into eight groups; where Group 1 served as normal control (NC) and received 5 mL distilled water per kg, while Groups 2 to 8 received (Efavirenz+Lamivudine+Tenofovir disoproxil fumarate [ELT 17.14 mg]), (Lamivudine+Nevirapine+Zidovudine [LNZ 9.28 mg]), (Abacavir+Lamivudine [AL 12.86 mg]), (Lamivudine+Zidovudine [LZ 6.43 mg]), (Fumarate de tenofovir disoproxil+Lamivudine [TL 8.57 mg]), (Atazanavir+Ritonavir [AR 5.71 mg]) and (Liponavir+Ritonavir [LR 3.57 mg]) per kg body weight respectively at therapeutic doses via oral route for 30 days, and thereafter sacrificed under anesthesia injection. Blood was obtained via cardiac puncture for hormonal assay, while testes were dissected out for histological assessments.

**Results:** Testosterone concentrations significantly ( $p < 0.05$ ) declined in the HAART and ART-administered groups compared to NC. Testicular microstructure demonstrated mild to moderate degeneration of the germinal epithelium in the HAART- and ART- groups compared to NC.

**Conclusion:** ELT was less gonadotoxic compared with LNZ, while LZ was the most gonadotoxic ART based on severity of alterations in the testicular hormone and microstructure.

**Keywords:** Highly active antiretroviral therapies, antiretroviral therapies, testes, histology

### Introduction

Globally an estimated 38.0 million people were living with human immunodeficiency virus (PLWHAs) at the end of 2019 up from 2017 figures which was 36.9 million infected persons.<sup>1,2</sup> Nigeria

accounted for 59 % of all new human immunodeficiency virus (HIV) infections in West and central Africa in 2016.<sup>3</sup> Morbidity and mortality associated with HIV/AIDS related infections has been drastically reduced by the advent of highly active antiretroviral therapy (HAART).<sup>4</sup> The antiretroviral therapy (ART) guidelines include use of the antiretroviral-combination drugs which encumber the onset of HIV, leading to reduced viral load, thereby prolonging the life span and improving the quality of life of the patient.<sup>5</sup> These therapies are a combination of two or more

Corresponding Author: Dr. Innocent A. Edagha, PhD

Department of Human Anatomy,  
Faculty of Basic Medical Sciences,  
University of Uyo, Nigeria.  
E-mail: [innocentedagha@uniuyo.edu.ng](mailto:innocentedagha@uniuyo.edu.ng)

antiretroviral drugs, usually nucleoside/nucleotide reverse transcriptase inhibitors (NRTIs) and protease inhibitors (PIs) or non-nucleoside reverse transcriptase inhibitors (NNRTIs).<sup>6,7</sup> WHO recommends lifelong ART for all people living with HIV, notwithstanding the level of their CD4 count, and the clinical stage of disease inclusive of pregnant and breastfeeding women.<sup>8</sup>

The male genital tract has been shown to be a sanctuary site for HIV, allowing the virus to persist, despite adherence to pharmacotherapy and a significant reduction in the plasma viral load.<sup>9</sup> Sanctuary site for HIV-1 simply means an anatomic site that is highly impermeable to some ARTs and in which viral replication continues during treatment.<sup>10</sup> It has been reported that the testes can be infected by HIV-1 early during acute infection and remain infected during the asymptomatic stage.<sup>11</sup>

Increase in abnormal sperm morphology, reduction in ejaculate volume and reduced potential to fertilize an oocyte could be associated with HAART.<sup>12,13</sup>

The testes are the male gonads, paired-ovoid shaped reproductive glands that produce sperms (spermatozoa) and male hormones, primarily testosterone.<sup>14</sup> This study investigated the gonadotoxic effects of some HAARTs and ARTs on the testicular testosterone and histomorphology in adult male Wistar rats.

## Materials and Methods

### Experimental animals

Forty (40) adult male Wistar rats weighing between 150 – 267g, aged 8 – 12 weeks were obtained from the Faculty of Basic Medical Sciences Animal House, University of Calabar, Cross River State, Nigeria. The animals were weighed, labelled and kept in wooden cages at the Animal House, Faculty of Basic Medical Sciences, University of Uyo, Akwa Ibom State, Nigeria, and were acclimatized for two weeks under optimum environmental conditions of temperature  $25 \pm 5^\circ\text{C}$  prior to the start of the experiment. Experimental animals were fed daily with pelletized growers (Vital<sup>®</sup> brand) and provided drinking water *ad libitum*. Rat cages were daily cleaned by changing the beddings. Animal care followed the already established principles of the National Guideline for the Care and Use of Laboratory Animals.<sup>15</sup>

### Drug acquisition

The highly active antiretroviral therapies (HAART) were two namely; Lamivudine (150 mg) + Nevirapine (200 mg) + Zidovudine (300 mg) (manufactured by Strides Acrolab Limited, Bangalore-562 106, India. Mfg. Lic.No.: KTK/25/415/98) and Efavirenz (600 mg) + Lamivudine (300 mg) + Tenofovir disoproxil fumarate (300 mg) (manufactured by Aurobindo pharma Limited, Telangana State, India. M.L.No./Licence Fab.No: 22/MN/AP/2009/F/R), and five ARTs which include; Atazanavir (300 mg) + Ritonavir (100 mg) (manufactured by Mylan Laboratories Limited, Maharashtra, India. Mfg.Lic. No./Lic. Fab. No.: NKD/89), Liponavir (200 mg) + Ritonavir (50 mg) (manufactured by Mylan Laboratories Limited, Maharashtra, India. Mfg.Lic. No./Lic. Fab. No.: NKD/89), Lamivudine (150 mg) + Zidovudine (300 mg) (manufactured by Mylan Laboratories Limited, Maharashtra, India. Mfg.Lic. No./Lic. Fab. No.: NKD/89), Abacavir (600 mg) + Lamivudine (300 mg) (manufactured by Mylan Laboratories Limited, Maharashtra, India. Mfg.Lic. No./Lic. Fab. No.: NKD/89) and Fumarate de tenofovir disoproxil (300 mg) + Lamivudine (300 mg) (manufactured by Hetero labs Limited, Telangana, India, Mfg. Lic. No.: 22/RR/AP/2001/F/R). All drugs were sourced from the Pharmacy Department of the University of Uyo Teaching Hospital, Uyo.

### Administration of experimental drugs

Tablets of experimental drugs were grounded into powder, dispersed in 400 mL of distilled water and administered through oral intubation. Dosages were calculated in per body weight of animals in relation to the clinical dose for a 70 kg man using the formula:

$$V(\text{mL}) = \frac{D(\text{g/kg}) \times P(\text{kg})}{C(\text{g/mL})}$$

Where D = dose used in the study; P = body weight of each animal; C = concentration of drug; V = volume of drug administered; and 1 kg = 1000g.

### Experimental Design

The male adult Wistar rats were weighed, marked and distributed into eight groups of five adult male Wistar rat per group. Group 1 represented the control and received 5mL distilled water per kg

body weight, groups 2 to 8 were administered 17.14 mg ELT, 9.28 mg LNZ, 12.86 mg AL, 6.43 mg LZ, 8.57 mg TL, 5.71 mg AR, and 3.57 mg LR per kg body weight respectively via oral route for 30 days.

### Determination of organosomatic index

The body weights of each animal were noted before treatment and after treatment (day 30). The weights of both testes of respective group of animals were also recorded. From the values, the organosomatic index was calculated for all rats according to the method of Vani and Reddy<sup>16</sup>, to determine the organ weight to body weight ratios as follows: Testis weight/ Final body weight (g) × 100.

### Determination of serum testosterone

Serum testosterone hormone concentration was estimated using a microplate enzyme immunoassay as described by Vani and Reddy<sup>17</sup>. The desired number of coated wells was secured in a holder. Ten microliter (10 µL) of standards, specimens and control were dispensed into appropriate wells. Anti-testosterone reagent (50 µL) was dispensed into each well and mixed thoroughly. Testosterone HRP conjugate reagent (100 µL) was dispensed into each well and incubated for 90 minutes at 37 °C. The micro-wells were then rinsed and flicked 5 times with wash buffer. TMB substrate (1000 µL) was dispensed to each well and gently mixed for 10 seconds. The mixture was incubated at room temperature (18 – 22 °C) for 20 mins. The reaction was stopped by addition of stop solution to each well and gently mixed for 30 seconds to ensure a complete colour change. Absorbance at 450nm was read within 15 mins with a microtiter plate reader.

### Histopathological assessment

After thirty (30) days administrations, animals were injected ketamine (40 mg/kg)/xylazine (5 mg/kg) anesthesia (Sigma Aldrich, Germany), and testes were harvested, weighed, morphometrically measured, then preserved in Bouin's fluid for six hours then transferred into 70% alcohol for 24 hours<sup>18</sup>, then further cleared, infiltrated in paraffin wax and sectioned at 5µm with a Leica RM2125 RTS microtome. The tissue on albumenized slides were stained with Haematoxylin and counterstained with Eosin<sup>19</sup>. Tissues slides were viewed under the light microscope by three independent

histopathologists and images were obtained after examination of least five fields with Amscope digital camera (MU 1000, China) attached to a microscope (Olympus - CX31, Japan).

### Statistical analysis

Data obtained from this study were analyzed using Graphpad 6 version II system package. Results were expressed as mean ± standard error of mean. One way ANOVA and multiple comparison and t-test were employed with the significance level at  $p < 0.05$ .

### Results

#### Effect of HAARTs and ARTs on body weight and organo-somatic index

The LNZ group had an increase in body weight while in ELT group showed minimal changes in the body weight of rats administered with HAART; the AL group had positive impact on the overall body weight gain while LR group had a very minimal increase in body weight of rats administered with ARTs. There was little or minimal increase of body weight in NC group compared to AL group which had a significant higher increase of body weight (Table 1).

#### Effect of HAARTs and ARTs on testicular morphometry

The testicular weights were decreasing and increasing in the drug-administered groups compared to the normal control. There was a higher increase of testicular weight in the AR group compared to the NC group while the AL group decreased beyond the NC group (Table 2).

The testicular length mostly had increase compared to the normal control with only one of the groups having a slight decrease. In the HAART administered groups, LNZ group had a decrease in the testicular length, while ELT group had a remarkable increase in the testicular length. In the ARTs administered group the AR group had a significant increase in the testicular length while AL group had a decrease in the testicular length (Table 2).

The testes of the administered groups were all increased in diameter compared to the normal control. In the HAARTs treated group ELT had an increase in the diameter while LNZ had the same

**Table 1. Effects of HAARTs and ARTs on Body Weight and Organo-somatic Index**

Group	Initial Body Weight (g)	Final Body Weight (g)	Changes in Body Weight (g)	% Change in Body Weight	Organo-somatic Index
NC	151.20 ± 0.37	155.80 ± 1.71	4.60 ± 1.34	2.96	0.64
ELT	173.20 ± 4.19	175.80 ± 4.58	2.80 ± 0.39	1.47	0.59
LNZ	167.00 ± 2.85	176.00 ± 7.54	9.00 ± 4.69	5.20	0.60
AL	151.60 ± 0.51	170.20 ± 5.50	18.60 ± 4.99	10.92	0.55
LZ	152.00 ± 1.55	159.00 ± 3.91	7.00 ± 2.36	4.40	0.65
TL	159.00 ± 1.92	170.00 ± 5.76	11.00 ± 3.84	6.47	0.60
AR	224.40 ± 10.74	233.00 ± 10.80	8.6 ± 0.1	3.69	0.52
LR	198.00 ± 2.41	199.80 ± 2.87	1.4 ± 0.46	0.7	0.57

Data is expressed as Mean ± Standard error of mean (SEM).

**Table 2. Effects of HAARTs and ARTs on testicular morphometry in Wistar rats**

Group	Testicular Weight (g)	Testicular Length (mm)	Testicular Diameter (mm)
NC	1.00 ± 0.03	15.70 ± 0.26	7.24 ± 0.29
ELT	1.03 ± 0.05	17.06 ± 0.74	8.75 ± 0.57
LNZ	1.04 ± 0.08	14.69 ± 0.49	7.24 ± 0.37
AL	0.93 ± 0.04	15.24 ± 0.47	7.95 ± 0.44
LZ	1.04 ± 0.08	17.29 ± 0.38	9.16 ± 0.24 <sup>c</sup>
TL	1.02 ± 0.04	17.06 ± 0.43	8.24 ± 0.30
AR	1.22 ± 0.04 <sup>a</sup>	17.79 ± 0.34 <sup>b</sup>	8.77 ± 0.18
LR	1.14 ± 0.05	16.08 ± 0.34	8.77 ± 0.21

Data is expressed as Mean ± Standard error of mean (SEM).

<sup>a</sup> significantly increased compared to NC, ELT, LNZ, AL, and TL

<sup>b</sup> significantly increased compared to LNZ and NC

<sup>c</sup> significantly increased compared to LNZ and NC

mean value as the normal control group while in the ART administered group the diameter of LA group was significantly increased compared to the other groups whose values were higher than the control group (Table 2).

### Effect of HAARTs and ARTs on Serum Testosterone

Blood was obtained via cardiac puncture, and centrifuged to obtain sera from which the testosterone concentrations were assayed. The testosterone concentrations were markedly decreased in all the drug administered groups when compared to the normal control. In HAART administered groups, ELT showed a higher serum testosterone concentration compared to the LNZ

group, whereas AL-administered group had the highest testosterone concentration compared to LA group (Fig. 1).

### Histopathological assessments

Photomicrograph of NC showed normal arrangement of spermatogenic cells with rays of migrating germinal cells within the seminiferous tubules. ELT micrograph showed normal arrangements of spermatogenic cells within the seminiferous tubules, with intact interstitial tissue cells. LNZ micrograph showed normal histo-architecture of the spermatogenic cells and well protected basement membrane of the seminiferous tubules. AL micrograph showed areas of mild necrotic degenerations of the spermatogenic cells

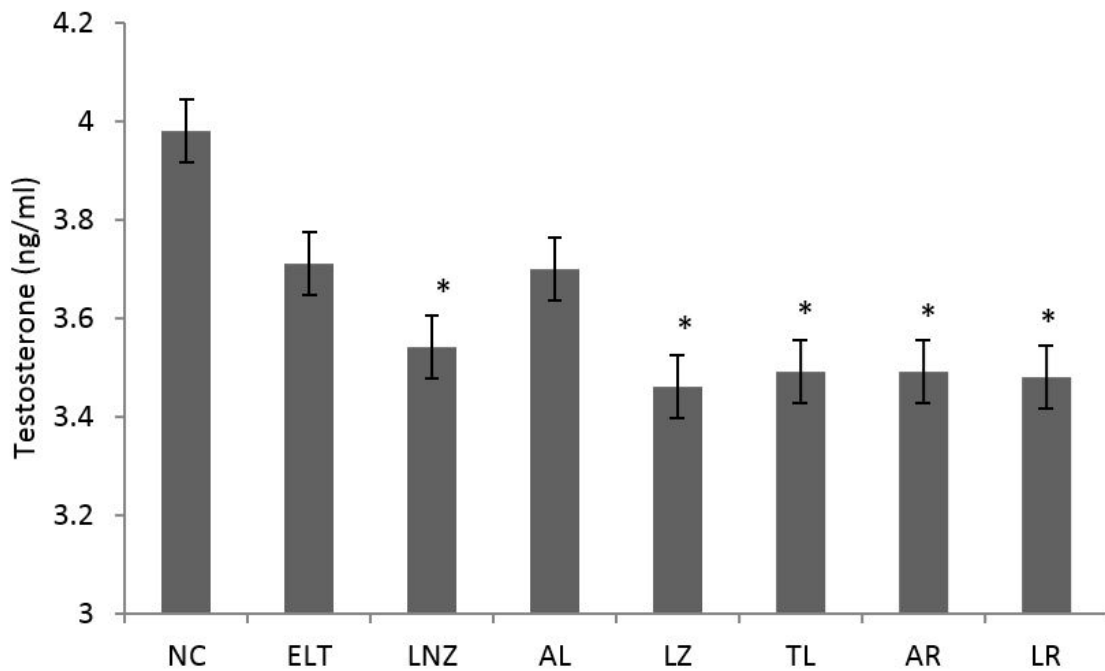
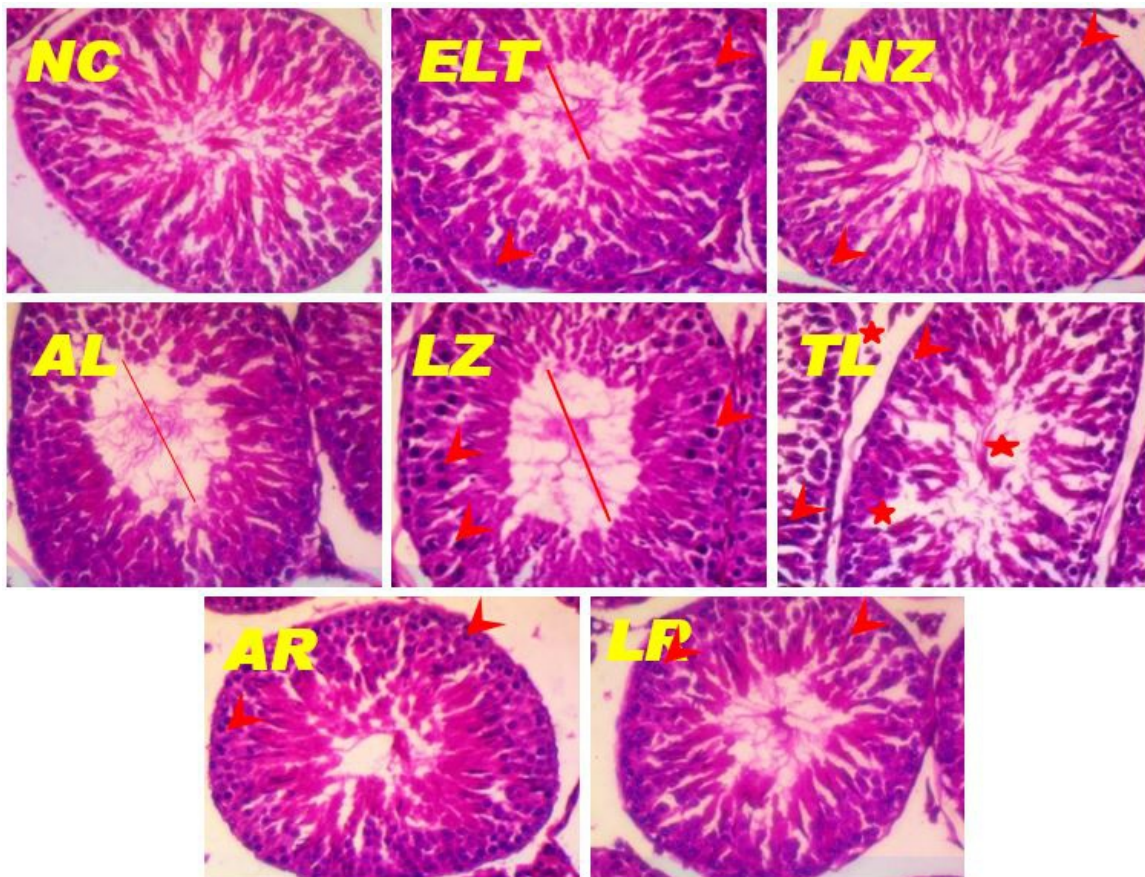


Fig. 1. Effect of HAART and ARTs on serum testosterone concentration in Wistar rats

**Histopathological Assessment**



**Figure 2:** Photomicrographs of transverse section of the testis (H&E x400). NC – Normal control which received placebo, and ELT – Efavirenz + Lamivudine + Tenofovir disoproxil fumarate, LNZ - Lamivudine + Nevirapine + Zidovudine, AL - Abacavir + Lamivudine, LZ - Lamivudine + Zidovudine, TL - Fumarate de tenofovir disoproxil + Lamivudine, AR - Atazanavir + Ritonavir, and LR - Liponavir + Ritonavir administered groups respectively.

**Legend:** Red line – width of seminiferous tubular lumen; Red arrow head – condensed nuclear; Red star – degenerated germinal epithelium.

with widened lumen within the seminiferous tubule. LZ micrograph showed areas of necrotic degenerations of the spermatogenic cells, hypertrophied spermatids, with widened lumen within the seminiferous tubules. TL micrograph showed areas of necrotic degeneration of spermatogenic cells, loss of interstitial connective tissues and presence of widened lumen. AR micrograph showed hyperplastic spermatogenic cells, within the seminiferous lumen. LR micrograph showed wide areas of cellular swellings with nuclear shrinkage, degenerating spermatogenic cells with widening tubular lumen within the seminiferous tubule shown in Fig. 2.

### Discussion

The body weight gain was significantly increased in the AL treated group when compared to the normal control and other administered groups. This observation presents the fact that AL administered may have a positive impact to the body weight index, and may not have the altered nutritional intake and genetic factors to body development. The result also showed that the LR treated group had the least body weight gain, which suggests an alteration to internal metabolism for body development.

Weight coefficient (organ/BW ratio) is a sensitive, effective and economic indicator of the toxicology of an organ and thus important in the identification of target organ of toxicants.<sup>20</sup> In this study, it was noted that the administration of HAARTs and ARTs produced significant changes in testicular weights; the NC group was lower than all the groups except AL group. The weight of the testes in the AR group was significantly increased following ART administration. This correlates with investigation that reported that testicular weight in HAART administered animals was significantly higher than those of controls.<sup>21</sup> Gonadotoxicity can manifest in the form of organ swelling, atrophy or

hypertrophy.<sup>22</sup>

The testosterone concentrations were significantly reduced in the test groups in comparison to the NC group, however the ELT and AL-administered groups had increased testosterone compared to other test groups. The LA-administered group had a testosterone concentration which was the lowest. Semen quality is a key factor determining reproductive success in men<sup>23</sup> especially as with chronic diseases,<sup>24</sup> and due to the increased incidence of toxicity of ART, it has necessitated proper evaluation of their effects on reproductive health.<sup>25</sup>

Testicular photomicrograph showed normal features in the NC group, with seminiferous tubules having normal testis histoarchitecture that were regularly spaced with all cells of the spermatogenic series and lumen of the seminiferous tubules populated by spermatozoa. Groups administered HAARTs showed mildly distorted seminiferous tubules with less observable degenerations to spermatogenic cells, whereas ART-administered groups revealed features of degeneration of seminiferous tubules and derangements in the histoarchitectural patterns. All the ARTs administered groups showed varying levels of necrotic effects as, hypertrophy with nuclear shrinkage, some hypertrophied nuclei, degenerated cells, widened tubular lumen and hyperplasia of the spermatogenic cells. It had been reported that HAARTs rather than HIV-1 were responsible for the topographic changes in sperm cells.<sup>26</sup> It has been reported that HAART induces negative changes on spermatogenesis by causing declines in testicular structure,<sup>21</sup> and this is supported by the findings of this study. Thus, the testicular morphological alterations can be attributed anti-HIV therapies, thus challenging the optimal management of the HIV infection long term.<sup>27</sup> Histopathological changes in the testes of patients dying of AIDS are

frequent, with common findings at autopsy including decreased spermatogenesis, thickened basement membrane and an interstitial infiltrate<sup>28</sup> but this study was limited to drug-induced testicular toxicities. During the 30-day treatment period, most of the tubular and epithelial areas in the testes of HAARTs and ARTs treated rats were not significantly altered in comparison with the negative control groups.

The long-term deleterious effects of antiretroviral drugs exposure to the male reproductive system may not be unrelated to the production of highly reactive oxygen radicals, and subsequent induction of oxidative stress.<sup>29</sup> Reactive oxygen species (ROS) can be generated by cellular and acellular mechanisms such as lymphocytes during HIV infection.<sup>26</sup> and drug toxicity.<sup>30,31</sup> respectively. Physiologically, ROS are required by spermatozoa to attain functional maturity.<sup>32</sup> These low levels of ROS are essential for normal fertilization, capacitation, hyperactivation, motility and acrosome reaction.<sup>33</sup> As spermatozoa acquire fertilizing ability in a favourable environment, capacitation occurs.<sup>34</sup>

Reproduction is a fundamental process that allows living organisms to preserve their progeny and evolve by transmitting genes. However, metabolism, which is supported by sex steroid hormones, is highly activated during spermatogenesis, indicating that the reproductive system itself generates high levels of ROS.<sup>35</sup> Damaging effect of HAART on the mitochondria could result in adverse effects on sperm motility.<sup>36-38</sup>

### Conclusion

Therapeutic doses of triple or double ART have deleterious effects on the testosterone concentrations and testicular histology after a 30-day oral administration, with ELT causing less damage compared to LNZ. Likewise, TL demonstrated the most testicular distortion, while AR elicited the least testicular alterations. Lifelong administration of ARTs will require supplementary adjuvants to mitigate effect of toxicity.

### Acknowledgments

Authors thank Mr Archibong Bassey of the Histology laboratory, Department of Human Anatomy, University of Uyo for his technical

assistance

### References

1. WHO. (2017). Global Action Plan on HIV Drug Resistance 2017 - 2021. <https://www.who.int/hiv/pub/drugresistance/hiv-drug-resistance-action-plan-2017-2021/en/> Accessed January 21, 2021.
2. WHO. (2020) HIV/AIDS – Fact sheets. <https://www.who.int/news-room/fact-sheets/detail/hiv-aids>. Accessed January 21, 2021.
3. UNAIDS. (2017). West and Central Africa Catch up Plan. Unicef. (2017). Statistical Update. <https://data.unicef.org/resources/children-aids-statistical-update/> Accessed January 21, 2021.
4. Emejulu, A. A., Ujowundu, C. O., Igwe, C. U. and Ouwuliri, V. A. (2010). Hepatotoxicity of Antiretroviral Drugs in HIV Seropositive Nigerian Patients. *Australia Journal of Basic and Applied Science*, 4: 4275 – 4278. doi:10.4103/2384-5147.144727.
5. Hughes, P. J., Cretton-Scott, E., Teague, A. and Wensel, T. M. (2011). Protease Inhibitors for patients with HIV-1 Infection: *A comparative Overview*. PT,36(6): 332–345.
6. Hunter, R. H. F. and Rodriguez-Martinez, H. (2004). Capacitation of Mammalian Spermatozoa in vivo, with a Specific Focus on Events in the Fallopian Tubes. *Molecular Reproduction and Development*, 67(2): 243 – 250. DOI: 10.1002/mrd.10390.
7. Saag, M. S., Powderly, W. G., Schambelan, M., Benson, C. A., Carr, A., Currier, J. S., Dubé, M. P., Gerber, J. G., Grinspoon, S. K., Grunfeld, C., Kotler, D. P. and Mulligan, K. (2002). Switching antiretroviral drugs for treatment of metabolic complications in HIV-1 infection: summary of selected trials. *Top HIV Medical*, 10: 47–51.
8. Pozniak, A. L., Gallant, J. E., DeJesus, E., Arribas, J. R., Campo, R. E., Chen, S. S., McColl, D., Enejosa, J., Toole, J. T. and Cheng, A. K. (2006). Tenofovir disoproxil fumarate, emtricitabine, and efavirenz versus fixed-dose Zidovudine/lamivudine and efavirenz in antiretroviral-naïve patients: Virologic, Immunologic and Morphologic Changes. A 96-week analysis. *Journal Acquired Immune*

- Deficiency Syndrome*, 43: 535 – 540. DOI: 10.1097/01.qai.0000245886.51262.67.
9. World Health Organization (2015). Guideline on when to start antiretroviral therapy and on pre-exposure prophylaxis for HIV. Pp 1 – 78. Geneva, Switzerland, ISBN 978 92 4 150956 5.
  10. Persidsky, Y., Ramirez, S. H., Haorah, J. and Kanmogne, G. D. (2006). Blood-brain barrier: structural components and function under physiologic and pathologic conditions. *Journal Neuroimmune Pharmacology*, 1: 223 – 236. DOI: 10.1007/s11481-006-9025-3.
  11. Grossman, Z., Meier-Schellersheim, M., Paul, W. E. and Picker, L. J. (2006). Pathogenesis of HIV Infection: What the Virus Spares is as Important as what it Destroys. *National Medicine*, 12: 289 – 295. <https://doi.org/10.1038/nm1380>.
  12. Le Tortorec, A., Le Grand, R., Denis, H., Satie, A.-P., Mannioui, K., Roques, P., Maillard, A., Daniels, S., Jégou, B. and Dejucq-Rainsford, N. (2008). Infection of semen-producing organs by SIV during the acute and chronic stages of the disease. *PloS One*, 3 (3): e1792 doi:10.1186/1742-4690-7-S1-P11.
  13. Nicopoullos, J. D., Almeida, P., Vourliotis, M., Goulding, R. and Gilling-Smith, C. (2010). A decade of sperm washing: clinical correlates of successful insemination outcome. *Human Reproduction*, 25: 1869 – 1876. DOI: 10.1093/humrep/deq134.
  14. Ahmad, G., Moinard, N., Jouanolou, V., Daudin, M., Gandia, P. and Bujan, L. (2011). In vitro Assessment of the Adverse Effects of Antiretroviral Drugs on the Human Male Gamete. *Toxicology in Vitro*, 25: 485 – 491. doi:10.1016/j.tiv.2010.11.020.
  15. Cheng, C. Y. and Mruk, D. D. (2012). The Blood-Testis Barrier and its Implications for Male Contraception. *Pharmacological Reviews*, 64: 16 – 64. doi:10.1124/pr.110.002790.
  16. National Research Council (2011) Guide for the Care and Use of Laboratory Animals. 8th edn, National Academies Press, Washington (DC), Pp 1–217. <https://doi.org/10.17226/12910>,
  17. Vani, M. L. and K. P. Reddy (2000). Effect of Fluoride accumulation on some enzymes of brain and gastronemius muscles of mice. *Fluoride*, 33: 17–26.
  18. Wu, A. (2006) Tietz Clinical Guide to Laboratory Tests, 4<sup>th</sup> Edition Pp 1 – 1856. Saunders, USA.
  19. Latendresse, J. R., Warbritton, A. R., Jonassen, H. and Creasy, D. M. (2002). Fixation of testes and eyes using a modified Davidson's fluid: comparison with Bouin's fluid and conventional Davidson's fluid. *ToxicolPathol*, 30(4): 524 - 533.
  20. Dhurba, G. (2015). Hematoxylin and eosin staining: principle, procedure and interpretation. *Histopathology*, 4:125 – 130. <http://laboratoryinfo.com/hematoxylin-and-eosin-staining/>.
  21. Asagba S., Adaikpoh M., Kadiri H. and Obi F. (2007). Influence of Aqueous Extract of Hibiscus Sabdariffa L. Petal on Cadmium Toxicity in Rats. *Biological Trace Element Research*, 115 (1): 45 – 57. Doi: 10.1385/BTER:115:1:47.
  22. Azu, O. O., Naidu, E. C. S., Naidu, J. S., Masia, T., Nzemande, N. F., Chuturgoon, A. and Singh, S. (2014). Testicular Histomorphologic and Stereological Alterations Following Short-Term Treatment with Highly Active Antiretroviral Drugs (HAART) in an Experimental Animal Model. *American Society of Andrology and European Academy of Andrology*, 2: 772 – 779. doi:10.1111/j.2047-2927.2014.00233.x.
  23. Afolayan A.J. and Yakubu M. T. (2009). Effect of Bulbinenatalensis Baker stem extract on the functional indices and Histology of the liver and Kidney of male Wistar rats. *Journal of Medicinal Food*, 12, 814 – 820. Doi: 10.1111/j.1365-2605.2008.00910.x.
  24. Van Der Steeg, J. W., Steures, P., Eijkemans, M. J., Habbema, J. D. and Hompes, P. G. (2007). Pregnancy is predictable: a large-scale prospective external validation of the prediction of spontaneous pregnancy in subfertile couples. *Human Reproduction*, 22: 536 – 542. <https://doi.org/10.1093/humrep/del378>.
  25. Basson, R. (2007). Sexuality in chronic illness: no longer ignored. *Lancet*, 369: 350 – 352. doi:10.1016/S0140-6736(07)60166-4.
  26. Oluwatosin, A. A., Olubukola, O. A., Olubusuyi, M. A. and Solomon, E. O. (2015). Lopinavir/Ritonavir, an Antiretroviral Drug



- Lowers sperm Quality and Induces Testicular Oxidative Damage in Rats. *Tokia Journal of Experimental Clinical Medicine*, 40 (2): 51–57.
27. Barboza, J. M., Medina, H., Doria, M., Rivero, L., Hernandez, L. and Joshi, N. V. (2004). Use of atomic force microscopy to reveal sperm ultrastructure in HIV-patients on highly active antiretroviral therapy. *Arch Androl*, 50(2):121 – 129.
28. Wohl, D. A. and Brown T. T. (2008). Management of Morphological Changes Associated with Antiretroviral used in HIV-infected patients. *Journal of Acquired Immune Deficiency Syndrome*, 2: 93 – 100. Doi: 10.1097/QAI.0b013e318186521a.
29. Pudney J. and Anderson D. (1991). Orchitis and human immunodeficiency virus type 1 infected cells in reproductive tissues from men with the acquired immune deficiency syndrome. 139 (1): 1 4 9 – 6 0 . <https://www.ncbi.nlm.nih.gov/m/pubmed/1853930/>.
30. Azu, O. O. (2012a). Highly Active Antiretroviral Therapy (HAART) and Testicular Morphology: Current Status and a case for a Stereologic Approach. *Journal of Andrology*, 33 : 1 1 3 0 – 1 1 4 2 . doi:10.2164/jandrol.112.016758.
31. Munoz, J. F., Salmen, S., Berrueta, L. R., Carlos, M. P. and Cova, J. A. (1999). Effect of human immunodeficiency virus type 1 on intracellular activation and superoxide production by neutrophils. *Journal of Infectious Diseases*, 180: 206–210. DOI: 10.1086/314821.
32. Skuta, G., Fischer, G. M., Janaky, T., Kele, Z. and Szabo, P. (1999). Molecular mechanism of the short-term cardiotoxicity caused by 2',3'-dideoxycytidine (ddC): modulation of reactive oxygen species levels and ADP-ribosylation reactions. *Biochemical Pharmacology*, 58: 1915 – 1925. [https://doi.org/10.1016/S0006-2952\(99\)00282-8](https://doi.org/10.1016/S0006-2952(99)00282-8).
33. Labbe, G., Pessayre, D. and Fromenty, B. (2008). Drug-induced liver injury through mitochondrial dysfunction: mechanisms and detection during preclinical safety studies. *Fundamentals of Clinical Pharmacology*, 22: 335 – 353. doi:10.1111/j.1472-8206.2008.00608.x.
34. Azu, O. O. (2012b). The Male Genital Tract in the Era of Highly Active Antiretroviral Therapy (HAART): Implication for Antioxidant Therapy. *Journal of AIDS Clinic Research*, 3: 169. doi:10.4172/2155-6113.1000169.
35. Agarwal, A., Nallella, K. P., Allamaneni, S. S. and Said, T. M. (2004). Role of antioxidants in treatment of male infertility: an overview of the literature. *Reproductive Biomedical Online*, 8: 616 – 627. doi:10.1016/S1472-6483(10)61641-0.
36. Hunter R.H.F. and H. Rodriguez-Martinez (2004) Capacitation of Mammalian Spermatozoa In Vivo, with a Specific Focus on Events in the Fallopian Tubes. *Molecular Reproduction and Development*, 67(2):243 – 250. DOI: 10.1002/mrd.10390.
37. Deeks, S. G. (2006). Antiretroviral Treatment of HIV Infected Adults. *British Medical Journal*, 332: 1489. doi:10.1136/bmj.332.7556.1489.
38. Van Der Valk, M., Bisschop, P. H., Romijn, J. A., Ackermans, M. T., Lange, J. M., Endert, E., Reiss, P. and Sauerwein, H. P. (2001). Lipodystrophy in HIV-1-positive patients is associated with insulin resistance in multiple metabolic pathways. *AIDS*, 15: 2093 – 2100. DOI: 10.1097/00002030-200111090-00004.
39. Van Leeuwen, E., Wit, F. W., Repping, S., Eeftinck-Schattenkerk J. K. M., Reiss, P., van der Veen, F. and Prins, J. M. (2008) Effects of antiretroviral therapy on semen quality. *AIDS*, 22 : 6 3 7 – 6 4 2 . D O I : 10.1097/QAD.0b013e3282f4de10.