



## Variability of optic nerve sheath diameter measurement on computed tomography; need for standardization

Itanyi UD<sup>1</sup>, Aiyekomogbon JO<sup>1</sup>, Atim TT<sup>1</sup>, Ambali-Belgore A<sup>2</sup>

<sup>1</sup>Department of Radiology, University of Abuja Teaching Hospital, Gwagwalada, Federal Capital Territory, Nigeria

<sup>2</sup>Department of Radiology, Faculty of clinical Sciences, University of Abuja, Nigeria

### Abstract

**Context:** Computed tomography measurement of optic nerve sheath diameter (ONSD) is established for the indirect evaluation of intracranial pressure in traumatic brain injury (TBI). There is however a significant difference in the reported values across different techniques with no clear-cut range of values agreed upon.

**Objective:** To measure the ONSD of patients with TBI and those with normal brains using different window settings and locations and compare with published values.

**Methodology:** Comparative evaluation of 300 ONSD measurements obtained from cranial CT examinations at the Radiology department of a tertiary institution. Seventy-five patients had radiologic signs of TBI while 75 had normal findings (controls). For each subset, ONSD was measured at 3mm and 8mm retrobulbar regions using spine window (ww/wl 250/50). ONSD was measured using additional settings (mediastinal ww/wl 450/60 and soft tissue 380/40) for controls. Correlation between age, gender, and side of the ONS complex at different lengths and contrast settings were also evaluated.

**Results:** The age range of the patients was 1-78 years, mean age of 40.4 years  $\pm$  21.7 with male: female ratio of 3:1. The mean ONSD was statistically different ( $p < 0.0001$ ) using the different window settings with the highest value obtained with the mediastinal window. There was also a significant difference ( $p < 0.0001$ ) between the ONSD of TBI and control patients at 8mm and 3mm retrobulbar regions but no correlation with gender, age, and side.

**Conclusion:** Significant variations in the CT measurements of ONSD with regards to retrobulbar locations and window settings highlight the need for standardization of protocols. Measurement taken at 3mm retrobulbar using a spine window setting shows greater distensibility and details of the optic nerve and allows for more reliable measurements.

Keywords: Optic nerve sheath diameter, computed tomography, window setting, variations, standardization.

### Introduction

The Gold standard for measurement of intracranial pressure, ICP is invasive and associated with complications such as hemorrhage, infections, tube dysfunction, and blockage. Raised ICP causes distension of the dural optic nerve sheath which can be measured indirectly using ultrasonography (US), computed tomography (CT), and magnetic resonance imaging (MRI). These have been validated as reliable indirect alternatives with studies showing a significant correlation between the measurements of ONSD in CT, USS, and MRI in terms of accuracy, sensitivity, specificity, and positive predictive value.<sup>1,2</sup>

#### Corresponding Author:

**Dr. Ukamaka Dorothy Itanyi**

Department of Radiology, University of Abuja Teaching Hospital, Gwagwalada, Federal Capital Territory, Nigeria.

[amakaitanyi1995@gmail.com](mailto:amakaitanyi1995@gmail.com) | +2348033240270

DOI: 10.61386/imj.v17i3.491

CT is the imaging modality of choice in acute trauma care settings and can evaluate both the pathology and effect of brain injury with other radiologic signs of raised intracranial pressure (ICP) seen. Despite these validations on the use of ONSD, there is as yet no consensus on the protocols and cut-off values for making a diagnosis of intracranial hypertension, ICH.

A review of existing measurement used by the different researchers thereby highlighting the limitations and importance of standardization of examination techniques.

Different researchers have indicated normal/abnormal threshold (a cutoff value) of the optic nerve sheath diameter from 4.8mm to 5.9mm with numerous variations between these numbers.<sup>3,4</sup> These differences are mostly due to disagreements on the exact position and anatomical plane of measurement, imaging modalities as well as window setting on CT. Lui and Kahn<sup>5</sup> have shown experimentally that the most pliant part of the optic nerve sheath is located in the region of its ampullar part with validation by Hansen and Helmke<sup>6</sup> who showed that ONSD increased by up to 60% at a distance of 3mm behind the globe in comparison to only 35% at 10mm. Measuring at this location is however not universally accepted with other authors suggesting measurements at the distal aspect of the optic nerve 8-10mm from the globe noting more stability of results with less standard deviation at these regions.<sup>7</sup> Others have used 4mm, 2 to 5mm behind the globe or not mentioning this distance at all.<sup>6,8,9</sup>

These variations in measurement are equally noted in the choice of window settings for evaluation of the optic nerve and brain since a thorough assessment of the organs is dependent on choosing the appropriate window setting on CT. Changes made in the window level and width settings on CT scanning have been shown to result in different values concerning the intraocular contents.<sup>8</sup> The use of different ranges of window and level settings, which bring into focus different levels of brightness and contrast, is the staple of the interpretation of images on CT.

The range for measurement of ONSD is very narrow and therefore precise, easy, and reproducible measurements are necessary for further validation of the use of ONSD as a reliable indirect measurement of ICP.

**Aim:** This study aims to assess the differences in computed tomography optic nerve sheath diameter measurements in patients with normal brains and those with radiologic signs of raised ICP using different retrobulbar locations and window settings.

### Materials and methods

This prospective study approved by the hospital ethical committee (HREC/PR/2020/010/008) was conducted over 15 months, from (March 2020 - June 2021). The study groups included 75 patients who

were referred for cranial CT examination at the Radiology department of a tertiary institution on account of traumatic brain injury (TBI) [Group A] and 75 Patients with relatively normal brain findings and non-ophthalmic clinical indications [Group B]. All studies were performed with a Hispeed Toshiba 16-slice CT scanner. The study subjects were placed in a supine position in the CT scanner gantry and scanned from the skull base to the vertex with contiguous axial slices parallel to the inferior orbitomeatal line using 5mm slice thickness at intervals of 3mm.

For each subset of patients, ONSD was measured at 3mm and 8mm retrobulbar regions on axial orbital CT images in a plane parallel to the optic nerve sheath complex. The superior ophthalmic vein was used as the landmark for the middle third for the orbital path of the optic nerve. All measurements were made by two experienced radiologists using the methodological procedures.

**CT window settings:** For Group A (TBI patients) bilateral ONSD measurements were taken at a constant window setting 50/250 (which demonstrated ONSD in complete and greatest detail).<sup>10,11</sup>

For Group B (control), ONSD was further measured at 3mm using the following window width (W) and level (L) based on previous studies, such as: 250/50 (spine),<sup>11</sup> 380/40 (soft tissue window)<sup>7</sup> and 450/40 (mediastinal window).<sup>12</sup> Correlation between age, gender, and diameter of the optic nerve sheath complex was also evaluated as well as the difference in size of the complex between both eyes. A comparison was made between the ONSD at the different levels (3mm and 8mm retrobulbar distances) and the different window settings (spine, soft tissue, and mediastinal). Excluded from the study were patients with clinicopathologic evidence of orbital pathology, asymmetric scans, and scans with artifacts for any reason (dental material, eye motion. etc.). The optic canal was measured and values <3.5mm were excluded.

The collected data was analyzed and interpreted accordingly. Descriptive statistics methods adopted were mean, median, minimum, maximum, and standard deviation. Student's t-test and Analysis of variance (ANOVA) test were used accordingly to test significant differences between various levels of variables under study, also Pearson correlation was used to evaluate the relationship between variables with the level of significance set at 0.05.

**Result**

The age of the patients ranged from 1 to 78 years old, (mean 40 ± 3.1) with 111(74%) males and 39 (26%) females in a ratio of 3:1. Seventy-five patients had radiologic signs of traumatic brain injury, while 75 had normal brain findings on CT. There was no statistically significant difference between the mean ONSD of the right and left optic nerves and genders however there was a significant difference in the mean ONSD at 3mm and 8mm retrobulbar regions in both subsets of patients. See Tables 1 and 2.

Comparison of ONSD at 3mm retrobulbar using different window settings showed a statistically significant (p<0.001) difference between the spine window (ww/wl 250/50), soft tissue window (380/40) and mediastinal window (450/40) with the highest values noted with mediastinal window setting. (Table 3, Fig 1A and B)

Table 1: Comparison of ONSD to side and gender

Variables	Measurements		t	P-value
	8mm Mean±SD	3mm Mean±SD		
<b>Group A (TBI)</b>				
Male				
Right ON	5.2±0.6	5.9±0.7	16.245	<0.001*
Left ON	5.1±0.5	6.0±0.6	13.679	
Female				
Right ON	5.4±0.5	6.0±0.6	4.378	0.001*
Left ON	5.4±0.3	6.1±0.5	5.355	
<b>Group B (normal)</b>				
Male				
Right ON	4.2±0.5	4.7±0.6	9.788	<0.001*
Left ON	4.2±0.6	4.8±0.5	11.906	
Female				
Right ON	4.1±0.6	4.6±0.5	8.306	<0.001*
Left ON	4.2±0.8	4.8±0.6	8.339	

\*Significant at 95% t =t-test statistic ON =optic nerve

Table 2: Comparison of ONSD measurements at 8mm and 3mm retrobulbar distances

Variables	Retrobulbar Distance		t	P-value
	8mm Mean±SD	3mm Mean±SD		
<b>Group A (TBI)</b>				
Right ON	5.2±0.6	5.9±0.6	16.358	<0.001*
Left ON	5.2±0.5	5.9±0.6	14.675	<0.001*
<b>Group B (normal brain)</b>				
Right ON	4.2±0.6	4.7±0.6	12.879	<0.001*
Left ON	4.2±0.6	4.8±0.6	14.586	<0.001*

\*Significant at 95% t-test statistic ON=optic nerve

Table 3: Comparison of ONSD measurements using spine, soft tissue, and mediastinal windows

Variables	Mean±SD	Median	CI	Range
Spine (ww/wl 250/50)	4.2±0.5	4.3	4.1-4.4	3.1-5.1
Soft tissue (380/40)	5.2±0.6	5.2	5.1-5.4	3.8-6.5
Mediastinal (450/40)	5.7±0.6	5.7	5.5-5.9	4.3-6.8
F	91.157			
P-value	<0.001*			

\*Significant at 95% F – ANOVA test statistic

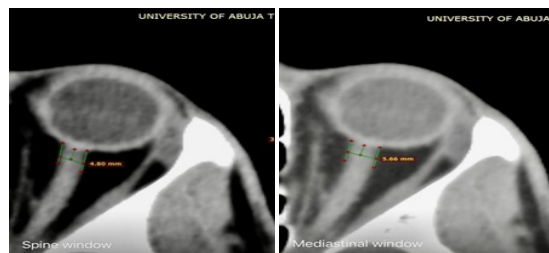


Figure 1: ONSD of the same patient on A: spine window (ww/wl 250/50) and B: mediastinal window (ww/wl 450/40).

**Discussion**

Despite the correlation between the different methods of ONSD measurement, there is still a disparity in the documented values for normal as well as threshold above which ICP is suspected with values depending on the imaging modality and technique of measurement. Published data on CT assessment of ONSD have quoted varied values based on different techniques and modalities of measurement. This lack of consensus on the precise method of assessment of ICP using the already validated indirect methods is disadvantageous considering the importance of early diagnosis and management of ICH.

Measuring at 3mm retrobulbar, the mean normal ONSD 4.7mm ± 0.6 (range 3.2-5.5mm) in this study is slightly higher than the study by Ozgen et al<sup>10</sup> using a similar window level and width, which recorded a mean ONSD of 4.4mm (normal range of 3.2–5.6mm) but comparable to study by Gupta et al<sup>13</sup> in an Indian population using the same location. They reported a mean optic nerve sheath diameter of 4.78mm. They did not use a fixed window setting but rather a window width ranging from 40–60 HU and center ranging from 250–300 HU was used which is within the range of the index study. The mean normal ONSD measured at 3mm retrobulbar in a study by Lim, et al<sup>14</sup> was similar to the index study at 4.7 ± 0.6. Though the measurement location is the same as our study, the contrast setting was not indicated making it difficult to compare.

Our study however differed from the study by Fidor-Mikita, et al<sup>11</sup> which reported mean ONSD as 5.2mm ± 0.8 despite similar retrobulbar location and window setting. It however should be noted that their study population included patients with thyroid orbitopathy with the majority (78.3%) presenting with proptosis, most likely contributing to the dissimilarity.

The mean ONSD measurement at the 8mm retrobulbar region was 4.2mm ± 0.6. This is comparable with the study by Lee, et al<sup>15</sup> in a Korean population which recorded a normal mean ONSD of 4.2 ± 0.6 using constant window level and width settings. A similar study in a Thai population recorded higher values of ONSD at the retrobulbar region (5.6mm±1.8) but lower measurements at the waist regions (3.7mm ± 0.8).<sup>16</sup> However, no window setting was included in this study making this irreproducible. A large prospective study involving 300 healthy adult patients showed that the ONSD varied from 3.55 +/- 0.82mm to 5.17 +/- 1.34mm in different locations with the most stable results with the least standard

deviation obtained when it is measured 8-10mm from the posterior margin of the globe<sup>7</sup>. This is different from the index study which had no significant difference in standard deviation at the different retrobulbar distances. We however noted the greatest difference and distensibility of ONSD at the 3mm retrobulbar location.

There was an appreciable variation in ONSD measurements on changing the window settings. On using the spine window, mean ONSD was 4.2mm  $\pm$  0.5 while mediastinal and soft tissue window measurements were 5.7mm  $\pm$  0.6 and 5.2mm  $\pm$  0.6 respectively. This confirmed the findings that changes made in the window level and width settings on CT scanning have been shown to result in different values with respect to the intraocular contents.<sup>8</sup> The statistical significance difference ( $P < 0.001$ ) in the window settings and better contrast resolution obtained with the spine window in this study was similarly observed by Fidor-Mikita et al.<sup>11</sup>

This variation of measured values with window settings is further reflected in the study by Vaiman, et al<sup>7</sup> using window settings (360/60) which showed a mean ONSD of 5.06mm at 3mm retrobulbar. Changing the contrast setting of our study to a comparable range (380/40) yielded a similar ONSD of 5.2mm  $\pm$  0.6. A study by Majeed, et al<sup>12</sup> using mediastinal window recorded a normal mean ONSD of 5.7mm  $\pm$  0.58 which is same with the index study which measured 5.7mm  $\pm$  0.6) using the mediastinal window. These findings further validate the need for standardization of the technique of measurement.

Regardless of the imaging modality or technique of measurement employed, ICP has been strongly correlated with ONSD in different studies. The mean ONSD of 75 patients with TBI was 5.3mm  $\pm$  0.5 and 6.0mm  $\pm$  0.6 at 8mm and 3mm retrobulbar respectively. This is lower than the study by Turkin, et al<sup>17</sup> and Waqas, et al<sup>18</sup> who recorded mean ONSD values of 6.0 mm and 6.7mm  $\pm$  0.82 respectively in patients in the acute TBI period. Although these studies involved measurements taken at 3mm axial CT scans, the exact contrast parameters were not indicated further validating the inconsistencies in technique and most likely accounting for the difference from our study.

CT-based measurement of ONSD has been found to be a more accurate criterion for the determination of ICH compared to such CT signs as compression of the lateral ventricles, smoothing of the border of white and gray matter, and lateral displacement.<sup>19</sup> It is therefore

imperative to recommend a cutoff point of ONSD at which ICH is most likely to occur. Different authors have proposed cut-off points ranging from  $\geq 4.8$ mm to 6.35mm based on the differing techniques and protocols of measurements with thresholds varying with each study method.<sup>14,17,20,21</sup> The different studies are however in agreement in the sense that no correlation was found between ONSD and age, gender, or side of measurement.

The narrow range for measurement of ONSD requires a more precise, easy, and reproducible protocol to make indirect evaluation of ONSD more reliable. This index study notes the important findings that ONSD measured via head CT correlates with other radiologic signs of raised ICP as well as highlighting the inhomogeneity of recorded values based on differences in technique of measurements. The greatest distensibility of the Optic nerve sheath was noted with measurement taken at 3mm retrobulbar region while the least standard deviation was noted using the spine window setting.

The study is limited by the fact that comparison was not done with the intraventricular monitoring which is the gold standard for evaluation of intracranial pressure and variability in the measurements by the different radiologists was not considered.

### Conclusion

This study shows significant variation in the Computed tomography measurement of Optic nerve sheath diameter depending on the retrobulbar distances and window width and levels used. Based on our findings and reviewed literature, we propose measurement taken at 3mm retrobulbar as the most distensible region using a spine window (ww/wl 250/50) which shows the margins of the Optic nerve sheath in greatest detail. This will possibly reduce variations in measurements, improve accuracy and further validate its use as a reliable indirect indicator of raised ICP.

### Acknowledgment

We acknowledge the Head of Department of Radiology department and secretarial staff for their input in this research.

### References

1. Kalantari H, Jaiswal R, Bruck I, Matari H, Ghobadi F, Weedon J, et al. Correlation of optic nerve sheath diameter measurements by computed



- tomography and magnetic resonance imaging. *Am J Emerg Med.* 2013; 31(11): 1595-1597.
2. Shirodkar CG, Munta K, Rao SM, Mahesh MU. Correlation of measurement of optic nerve sheath diameter using ultrasound with magnetic resonance imaging. *Indian J Crit Care Med.* 2015; 19(8): 466-470.
  3. Kimberly HH, Shah S, Marill K, Noble V. Correlation of optic nerve sheath diameter with direct measurement of intracranial pressure. *Acad Emerg Med.* 2008;15(2):201-4. doi: 10.1111/j.1553-2712.2007.00031.
  4. Geeraerts T, Launey Y, Martin L, Pottecher J, Vigue B, Duranteau J, et al. Ultrasonography of the optic nerve sheath may be useful for detecting raised intracranial pressure after severe brain injury. *Intensive Care Med.* 2007;33(10):1704-1711.
  5. Liu D, Kahn M. Measurement and relationship of subarachnoid pressure of the optic nerve to intracranial pressures in fresh cadavers. *Am J Ophthalmol.* 1993 Nov 15; 116(5):548-56.
  6. Hansen HC, Helmke K. Validation of the optic nerve sheath response to changing cerebrospinal fluid pressure: ultrasound findings during intrathecal infusion tests. *J Neurosurg.* 1997;87:34-40.
  7. Vaiman M, Sigal T, Kimiagar I, Bekerman I. Noninvasive assessment of the intracranial pressure in non-traumatic intracranial hemorrhage. *J Clin Neurosci.* 2016;34:177-181.
  8. Kimberly HH, Noble VE. Using MRI of the optic nerve sheath to detect elevated intracranial pressure. *Crit Care.* 2008;12(5):181.
  9. Maude RJ, Barkhof F, Hassan MU, Ghose A, Hossain A, Abul Faiz M, et al. Magnetic resonance imaging of the brain in adults with severe falciparum malaria. *Malar J.* 2014;13:177.
  10. Ozgen A, Ariyurek M. Normative measurements of orbital structures using CT. *AJR Am J Roentgenol.* 1998 Apr; 170(4):1093-6
  11. Fidor-Mikita E, Krupski W. Computed tomography imaging of orbits in thyroid orbitopathy. *J Pre-Clin Clin Res.* 2008;2:059-063.
  12. Majeed G, Kashyap S, Menoni R, Miulli D, Sweiss R. A noninvasive method for the estimation of increased intracranial pressure in patients with severe traumatic brain injury using optic nerve sheath diameter measured on computed tomography head. *Surg Neurol Int.* 2019; 10: 197
  13. Gupta V, Prabhakar A, Yadav M, Khandelwal N. Computed tomography imaging-based normative orbital measurement in Indian population. *Indian J Ophthalmol* 2019 May;67(5):659.
  14. Lim TK, Yu BC, Ma DS, Lee GJ, Lee MA, Hyun SY et al. Correlation between optic nerve sheath diameter measured by computed tomography and elevated intracranial pressure in patients with traumatic brain injury *J Trauma Inj.* 2017;30(4):140-4.
  15. Lee HC, Lee WJ, Dho YS, Cho WS, Kim YH, Park HP. Optic nerve sheath diameter based on preoperative brain computed tomography and intracranial pressure are positively correlated in adults with hydrocephalus. *Clin Neurol Neurosurg.* 2018;167:31-35.
  16. Watcharakorn A, Ngamsirisuk S. Normal measurements of size of optic nerve sheath complex using computed tomography. *J Med Assoc Thai.* Chotmaihet thangphaet. 2014;97:S22-6.
  17. Turkin AM, Oshorov AV, Pogobekyan EL, Smirnov AS, Dmitrieva AS. Correlation of intracranial pressure and diameter of the sheath of the optic nerve by computed tomography in severe traumatic brain injury. *Zh Vopr Neurokhir Im NN Burdenko.* 2017;81(6):81-8.
  18. Waqas M, Bakhshi SK, Shamim MS, Anwar S. Radiological prognostication in patients with head trauma requiring decompressive craniectomy: Analysis of optic nerve sheath diameter and Rotterdam CT Scoring System. *Jour of Neuroradi.* 2016;43(1):25-30.
  19. Sekhon MS, Griesdale DE, Robba S, McGlashan N, Needham E, Walland K, et al. Optic nerve sheath diameter on computed tomography is correlated with simultaneously measured intracranial pressure in patients with severe traumatic brain injury. *Intensive Care Med.* 2014;40:1267-1274.
  20. Luyt D, Hurter D, Joubert G. The relationship between computed tomography measurement of the optic nerve sheath diameter and elevated intracranial pressure in non-trauma patients. *SA Journal of Radiology.* 2016;20(1):1-4.
  21. Öz Saraç M, Düzgün F, Gölcük Y, Pabuşcu Y, Bilge A, İrik M, Yılmaz H. Multislice computed tomographic measurements of optic nerve sheath diameter in brain injury patients. *Ulus Travma Acil Cerrahi Derg.* 2018;24(4):316-20.