



## Giant juvenile fibroadenoma in a 15-year-old Nigerian female: A case report with review of literature

O.J. Uchendu<sup>1</sup>, U. Umeaku<sup>1</sup>, M.O. Ajagha<sup>2</sup> and E. Ejuvwevwo<sup>1</sup>

<sup>1</sup>Department of Morbid Anatomy, Delta State University Teaching Hospital, Oghara, Delta State.

<sup>2</sup>Department of Surgery, Asaba Specialist Hospital, Asaba, Delta State.

### Introduction

Breast masses in female adolescents are rare and consist mainly of developmental lesions and benign tumours.<sup>1</sup> The benign tumours seen are mostly fibroadenoma which is the most common breast tumour seen in adolescent females.<sup>2</sup> It may present as solitary or multicentric tumour.<sup>3</sup> It may also vary in size and is designated as giant juvenile fibroadenoma “GJF” if it is greater than 5cm, 500g or replaces at least 80% of the breast tissue.<sup>3</sup> GJF accounts for 1-8% of breast lesions in the adolescent population.<sup>3,4</sup> Overall, giant fibroadenoma accounts for 0.5-2% of all fibroadenomas.<sup>4</sup> We present a case of GJF in a 15-year-old female who was managed in our clinical setting.

### Case report

Patient is a 15-year old girl who presented with a year history of right breast lump. Lump was initially small in size but increased rapidly to over 20 times its initial size over the following 6 months. There was no associated pain or nipple discharge, no lump in the contralateral breast or axilla. On examination at presentation, she was not in any distress, afebrile, not pale, anicteric, acyanosed and well hydrated. The significant findings were in the right breast. The breast was asymmetrically enlarged with the size of the right breast about twice of the left with dilated veins on the skin of the right breast. There was a huge mass occupying almost the entire 4 quadrants of the right breast. The mass measured approximately about 28.0 x 18.0 x 12.0cm with firm and cystic areas. It was freely mobile, with no attachment to the skin or underlying tissues. There were no clinically enlarged axillary lymph nodes. A diagnosis of giant fibroadenoma was made with a differential of cystosarcoma phyllodes.

A full blood count, electrolyte and urea and an ultrasound scan was done. She subsequently underwent excisional biopsy under general anaesthesia with a histologic diagnosis of giant fibroadenoma.

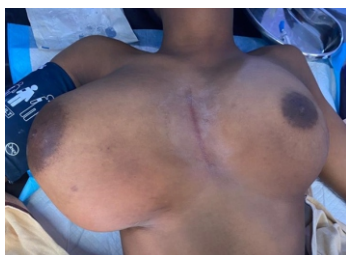

Figure 1: Photograph showing right breast enlargement

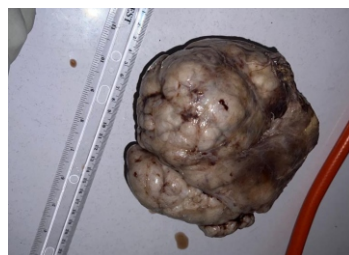

Figure 2: Photograph of the excised right breast lump

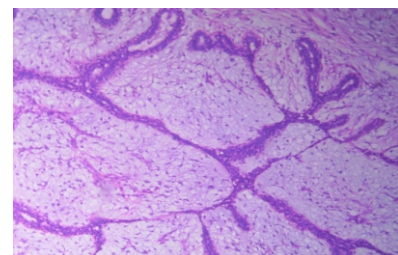


Figure 3: Photomicrograph showing the histology of the excised breast lump (H&E stain x40)

#### Corresponding Author:

**Dr. O.J. Uchendu**

Department of Morbid Anatomy, Delta State University Teaching Hospital, Oghara, Delta State, Nigeria.

ugoumeaku@gmail.com

DOI: 10.61386/imj.v17i1.395

#### Discussion

The adolescence age is unique as it heralds transition from childhood to adulthood. Any abnormal change in breast symmetry or presence of breast mass within this age is usually a concern to the family and patient. GJF is a serious source of anxiety to both patient and family. It may also be

associated with cosmetic changes including breast asymmetry, skin changes and deviation of nipple areola complex. Because of the size, it may also cause significant discomfort to the patient, and the pressure effect of the tumour may adversely impede normal development of the ipsilateral breast.<sup>5</sup> Malignancy is often a major dreaded consideration for large breast masses and may evoke a lot of psychological and emotional problems. This was observed by other Nigerian authors and this consideration was particularly so when there was associated skin ulceration.<sup>6-8</sup> Incidence of malignancy arising from GJF is however very rare.

Although aetiology is unknown, hormonal factors (mainly oestrogen stimulation) are implicated.<sup>2</sup> Genetic predisposition may play a role as has been supported by positive family history and higher incidence in African-American females.<sup>9</sup>

Differential diagnosis of GJF include phyllodes tumour, hamartoma, lipoma, pseudoangiomatous stromal hyperplasia and inflammatory process. Typical diagnostic workup includes patient history, physical examination and radiological evaluation, particularly ultrasonography. Typically, fibroadenoma presents as non-tender mobile mass with smooth borders. Diagnostic difficulty usually arises from physical examination and radiological evaluation because of convergent features. Definitive diagnosis is by histological evaluation using core needle biopsy, incisional biopsy or excisional biopsy specimen. Histologically, it consists of two patterns intracanalicular and pericanalicular, with proliferating fibromyxoid stroma that are compressing the ducts into elongated structures.

Goal of treatment is complete tumour excision, preservation of nipple and areola as well as achievement of bilaterally symmetrical breast. Treatment is conservative as risk of malignancy is nearly non-existent in this age group less than 20 years.

### Conclusion

GJF is an uncommon breast tumour. We report a case which was managed by us. Simple excision with inframammary approach was adopted to ensure better cosmesis and gratifying outcome. Histological examination of the excised lump is required to make a definite diagnosis. This is

important so as to reassure the patient that the lump is not malignant.

### References

1. Kaneda HJ, Mack J, Kasales CJ, Schetter S. Pediatric and Adolescent Breast Masses: A Review of Pathophysiology, Imaging, Diagnosis, and Treatment. *Am J Roentgenol*. 2013;200(2):204–12.
2. Rosen PP. Fibroepithelial Neoplasms. In: Rosen PP, editor. *Rosen's Breast Pathology*. 3rd edition. Philadelphia: Lippincott Williams & Wilkins; 2009. p. 187–229.
3. Jayasinghe Y, Simmons PS. Fibroadenomas in adolescence. *Curr Opin Obstet Gynecol*. 2009;21(5):402–6.
4. Mukhopadhyay M, Patra R, Mondal S, Ghosh A, Ray AK. Bilateral giant juvenile fibroadenoma of breasts. *J Indian Assoc Pediatr Surg*. 2009;14(2):69.
5. Davis SE, Wallace AM. A 19 Year Old with Complete Androgen Insensitivity Syndrome and Juvenile Fibroadenoma of the Breast. *Breast J*. 2001;7(6):430–3.
6. Nwashilli N, Obahiagbon I. Giant Fibroadenoma in a Middle-Aged Woman Requiring Mastectomy: A Case Report. *Annals of Health Research*. 2020 Nov 25;6(4):456–62.
7. Arowolo OA, Akinkuolie AA, Adisa AO, Obonna GC, Olasode BJ. Giant fibroadenoma presenting like fungating breast cancer in a Nigerian teenager. *Afr Health Sci*. 2013 Apr 12;13(1):162–5.
8. Achebe JU, Njeze GE, Okwesili OR. Treatment of unilateral giant fibroadenoma by breast reduction skin incision: The inverted 'T' technique. *Niger J Clin Pract*. 2014 Jan;17(1):43–6.
9. Baral S, Gyawali M, Thapa N, Chhetri RK, Dahal P. Giant juvenile fibroadenoma in an adolescent female: A case report. *Clin Case Rep*. 2020;8(12):3488–92.