



Comparative study of sonourethrography and conventional urethrography in determining the length of anterior urethral strictures

Umeh OE¹, Elendu KC¹, Aronu ME¹, Okafor C¹, Mbaeri TU², Uwanuruochi K³, Umeokafor C¹, Nwammuo C¹, Nwosu C¹

¹Radiology department, Nnamdi Azikiwe University Teaching Hospital Nnewi (NAUTH) Nnewi, P.M.B 5025 Nnewi, Anambra state, Nigeria

²Division of Urology, Department of Surgery, Nnamdi Azikiwe University Teaching Hospital, Nnewi, Anambra State, Nigeria

³Department of Medicine, College of Medicine and Health Sciences, Gregory University Uturu, Amachara campus & Department of Medicine, Federal Medical Centre, Umuahia, PMB 7001 Umuahia, Nigeria

Abstract

Background: Conventional urethrography has been the “Gold standard” in the evaluation of anterior urethral strictures. Sonourethrography (SUG) is less invasive, more readily available, and cheaper and does not use ionizing radiation.

Objective: To determine the length of anterior urethral strictures diagnosed on conventional urethrography using SUG and compare findings on SUG with conventional urethrography in adult male patients

Methodology: This was a prospective cross-sectional study carried out over a period of twelve months, whereby 66 male patients with clinically suspected anterior urethral strictures and confirmed on retrograde urethrography (RUG)/ Micturatingcystourethrography (MCUG) were examined using SUG. The length of anterior urethral strictures from both procedures were compared. The data analysis was done using statistical package for social sciences (SPSS) version 23(SPSS Inc, IL, USA). At 95% confidence interval, P-value ≤ 0.05 was considered statistically significant.

Result: Sixty six patients were studied. The mean age of the participants was 56.7 ± 13.7 years with an age range of 20 – 78 years. The stricture lengths and diameters were consistently higher on SUG compared to conventional urethrography. The mean length of stricture on RUG/MCUG and SUG were 19.4 ± 6.0 mm and 21.3 ± 6.7 mm respectively. The mean difference for the stricture lengths on RUG/MCUG and SUG was 1.9 mm and this was statistically significant (CI = 0.983 – 2.761, $p < 0.001$). The mean diameter of the stricture on RUG/MCUG and SUG were 2.2 ± 0.7 mm and 5.6 ± 1.2 mm and the mean difference for the stricture diameter on both techniques was 3.4 mm (CI = 3.158 – 3.577, $p < 0.001$), which was statistically significant.

Conclusion: Significantly higher mean stricture length and diameter were found on SUG compared with RUG/MCUG.

Keywords: Sonourethrogram, Conventional urethrogram, Stricture length and diameter.

Corresponding Author:

Dr. Elendu Kelechi Collins

Radiology Department, Nnamdi Azikiwe University Teaching Hospital Nnewi, P.M.B 5025, Nnewi, Anambra state, Nigeria

ekaycollin@gmail.com | +2348035744164

Orcid no: 0009-0006-0560-9052

DOI: 10.61386/imj.v17i1.389

Introduction

Conventional urethrography i.e. retrograde urethrography (RUG) and micturating cystourethrography (MCUG), has been the gold standard procedure used in evaluating urethral strictures despite its associated exposure to ionizing radiation and underestimation of the stricture length as well as not identifying the co-existing peri-

urethral fibrosis.¹ Sonourethrography was first described in 1988 by McAninch et al² and they reported more accurate measurement of anterior urethral strictures when compared with conventional urethrography. However, SUG is still under-utilized in our environment. The aim of this study was to compare the length of anterior urethra strictures between ultrasound and to compare the findings to those noted on conventional urethrography.

Methodology

This was a prospective cross-sectional study carried out from January 2020 to December 2020 in the Radiology department of Nnamdi Azikiwe University Teaching Hospital, a tertiary health institution located in Nnewi, Anambra State (601'N 6055'E)³ was the study site. Recruited subjects were males aged 18 years and above with clinically suspected anterior urethral stricture. The proposal was reviewed and approved by the Research and Ethical Committee of NAUTH.

Clinical Evaluation: Recruited patient underwent both conventional urethrography and sonourethrography. RUG was done before SUG. Fluoroscopy machine used was GE Precision RXi (GE Healthcare, 2009) with over couch tube. Stricture(s) were appreciated as area(s) of luminal narrowing(s) (figure 1) and the length of the strictures were measured including the tapered, with the aid of the electronic caliper which was available on the monitor. The corrected length of the stricture was obtained by dividing the length gotten from the image by a magnification factor of 1.2.4 For MCUG, the urinary bladder was filled with about 300 to 400 mls of dilute Urografin through a Foley catheter (size 10-F) in those with incomplete urethral obstruction or through a suprapubic catheter. After full distension of the urinary bladder with dilute Urografin, the patient was urged to strain with the catheter still anchored at the fossa navicularis and contrast gently introduced (Synchronous RUG and MCUG⁵) to enable the measurement of the exact length of the stricture.

For SUG, the ultrasound machine used was ALOKA Prosound SSD-3500SX (ALOKA Inc, Japan 2008) with high frequency (7.5-10 MHz) linear transducer. Anterior urethra was assessed in both

longitudinal and transverse planes. Strictures appeared as non-distensible luminal narrowing with tapered ends, appreciated while scanning the ventral aspect of the penis. The length and diameter of stricture was assessed thoroughly. Categorization of stricture length into two groups; short and long strictures, was done considering the required surgical management. Short strictures are those less than 2.5cm in length and long strictures (Figure 2) measure more than 2.5 cm in length.⁶

Statistical Analysis: The data analysis was done using statistical package for social sciences (SPSS) version 23 (SPSS Inc, IL, USA). At 95% confidence interval, P-value ≤ 0.05 was considered statistically significant.

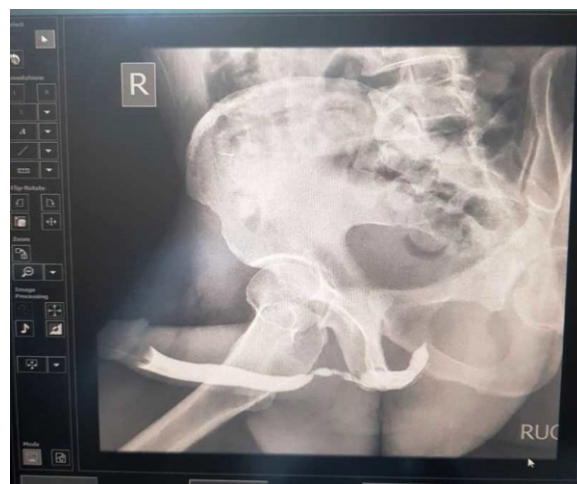

Figure 1: Long segment anterior urethral stricture on RUG

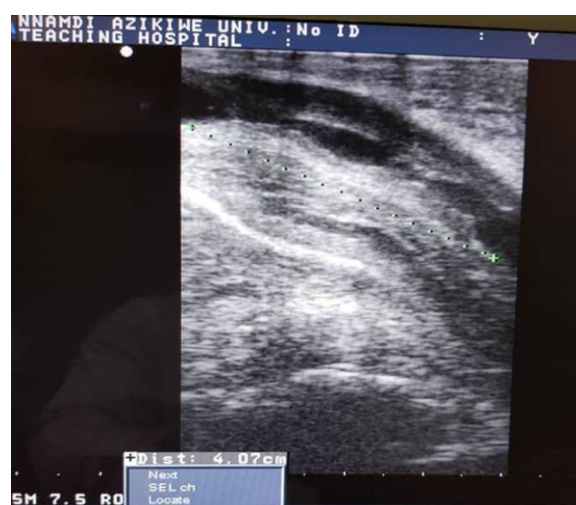

Figure 2: Sonogram showing long segment anterior urethral stricture

Table 1: Socio-demographic characteristics of the participants

Variables		Frequency (N = 66)	Percentage (%)
Marital Status	Married	53	80.3
	Single	13	19.7
Mean age in years	± Standard Deviation	56.7 ± 13.7	
Age groups(years)	Under 25	3	4.5
	26 – 35	6	9.1
	36 – 45	4	6.1
	46 – 55	8	12.1
	56 – 65	29	43.9
	66 – 75	14	21.2
	≥ 76	2	3

Table 2a: Correlation of mean stricture length and diameter on SUG and conventional urethrography

Variable		Mean	S.D.	Correlation	t-test	p-value
Length (in mm)	RUG	19.4	6.0	r = 0.848, p < 0.001	-4.207	< 0.001
	SUG	21.3	6.7			
Diameter (in mm)	RUG	2.2	0.7	r = 0.738, p < 0.001	-32.138	< 0.001
	SUG	5.6	1.2			

Table 2b: Classes of the strictures

Variables		Frequency	Percentage (%)
RUG	Short	56	84.8
	Long	10	15.2
	Total	66	100.0
SUG	Short	47	73.4
	Long	17	26.6
	Total	64	100.0

Results

A total of 66 patients were examined over a period of twelve months, using conventional urethrography and SUG.

The sociodemographic characteristics of study population is described in Table 1.

The stricture measurements by SUG were consistently higher than the measurements by conventional urethrography. For stricture length, the mean value by RUG/MCUG was 19.4 ± 6.0mm and by SUG was 21.3 ± 6.7mm. The mean difference was 1.9mm, which was statistically significant (p < 0.001) (table 6a). For stricture diameter, the mean value using were 2.2 ± 0.7mm and 5.6 ± 1.2mm on RUG/MCUG and SUG respectively and the mean difference was 3.4mm, which was also statistically significant (p < 0.001) (table 2a)

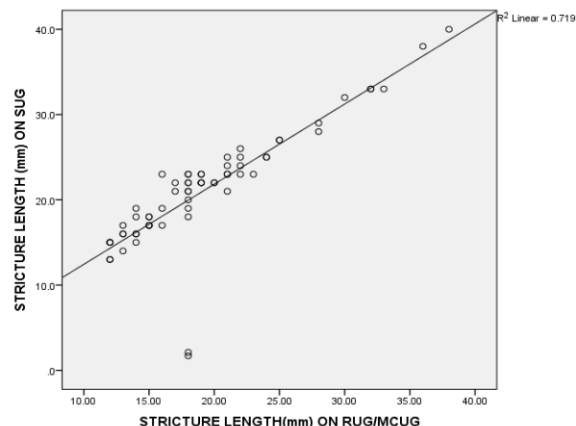


Figure 3: Correlation between stricture lengths on SUG and conventional urethrography

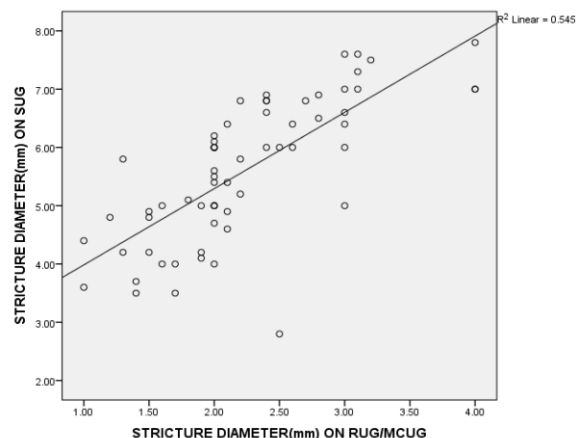


Figure 4: Correlation between stricture diameters on SUG and conventional urethrography

Classifying anterior urethral strictures into short (< 2.5cm) and long (≥ 2.5 cm) strictures, 56 (84.4%) of the strictures detected by conventional urethrography were short strictures. Likewise, most of the anterior urethral strictures detected by SUG, 47 (73.4%) were also short urethral strictures. SUG detected 17 (26.6%) long strictures while conventional urethrography detected 10 (15.2%) long strictures (table 2b).

In this study, SUG and conventional urethrography showed high positive correlation and significant relationship in the measured stricture lengths (n=64; r=0.848; p< 0.001) (figure 3) and stricture diameters (n =64; r = 0.738; p < 0.001) (figure 4) in all the 64 anterior urethral strictures detected by both.

Discussion

The results from this study showed that the length of

anterior urethral strictures and diameter measured on SUG were higher than the measurements obtained on conventional urethrography. Similarly, Khan et al⁷ in their study carried out at Pakistan Navy Ship (PNS) Shifa hospital, Karachi from January to December, 2004 which involved 40 male patients aged 17-61 years with a mean age of 39 ± 13 years, who were referred on account of obstructive urinary symptoms and underwent both conventional contrast urethrography and sonourethrography. From their results, the mean stricture length estimated by conventional urethrography and SUG were 12.512mm and 17.691mm, respectively. The difference between the two modalities was statistically significant ($P < 0.0001$). Comparably, Priyadarshi et al⁸ in their study done between March 2009 and February 2010 at Indira Gandhi Institute of Medical Sciences, Patna also reported that stricture lengths on SUG were higher than those on RUG. In their study, they used intraoperative findings as the Gold standard. They reported the mean lengths as 20.46mm, 17.14mm, and 20.35mm for SUG, RUG and intraoperative findings, respectively. Likewise, Nitin and colleagues⁹ in a similar study reported mean lengths of 38mm, 20mm and 35mm for SUG, RUG and intraoperative findings, respectively. Collectively, from their results, the mean stricture lengths on SUG were higher than the mean stricture length on RUG and also closer to the intraoperative findings.

From this study, the mean length of anterior urethral stricture was 21.3 ± 6.70 mm and 19.4 ± 6.0 mm for SUG and conventional urethrography respectively with a mean difference of 1.9mm, which was statistically significant ($CI = 1.123-3.232$, $p < 0.001$). In a comparative study of ascending urethrography and sonourethrography, carried out in JSS hospital, Mysore from March 2011 to March 2012 by Ravikumar and colleagues¹⁰ on Forty (40) male patients ranging between 25-75 years who presented with obstructive urinary symptoms suggestive of urethral stricture, conventional urethrography gave an average stricture length of 9.3mm while sonourethrography gave an average stricture length of 14.1mm. The mean difference between the two modalities was 4.8mm ($P < 0.01$). Akpayak et al¹¹ in a study carried out at Jos University Teaching Hospital (JUTH),

Jos, Nigeria reported mean length of the anterior urethral strictures as 16.0 ± 2.1 mm and 14.1 ± 1.9 mm for SUG and conventional urethrography, respectively, with a mean difference of 2.0 mm which was also statistically significant ($CI = 0.872 - 2.911$, $p \leq 0.05$). Relating the result from this study, in terms of the mean of the anterior urethral stricture lengths measured by SUG and conventional urethrography to the studies that used intraoperative finding as Gold standard and reported that the stricture lengths on SUG were closer to the intraoperative findings, it can be inferred that RUG underestimates the stricture length. The above observations may be due to the oblique alignment of the axis of the urethra being examined by x-rays, especially at the bulbar urethra. However, during SUG the transducer is in the mid sagittal plane on the ventral aspect of the penis along the axis of measurement perpendicular to the urethra. The degree of stretch of the penis during conventional urethrography has also been considered as a contributory factor in the underestimation of the stricture length.¹²

Underestimation of stricture length on conventional urethrography accounted for the greater number of long anterior urethral strictures on SUG, which were 17 in this study while on conventional urethrography 10 long strictures were noted. Accurate measurement of stricture length provides important information to the urologist in preoperative decision making in terms of the surgical approach to adopt. Short strictures may be treated by urethral dilatation, internal urethrotomy or anastomotic urethroplasty while long strictures require reconstructive surgery with flap graft urethroplasty.

In this study, SUG and conventional urethrography showed high positive correlation and significant relationship in the measured stricture lengths ($n=66$ $r=0.848$; $p < 0.001$) and stricture diameters ($n=66$ $r=0.738$; $p < 0.001$) in all the anterior urethral strictures detected by both modalities. Conventional urethrography detected 66 strictures and SUG detected 64. Comparably, in a study done by Nzeh and colleagues¹³ at University of Ilorin university teaching hospital between December 1995 and July 1996, on 14 male patients who presented with suspected urethral pathology also reported a good correlation in the findings on SUG and RUG. Dolaet

al¹⁴ in their study also reported that the Pearson correlation coefficient (r) was 0.95 for length measurement ($p < 0.01$) and 0.837 for diameter ($p < 0.01$).

The mean stricture diameter on SUG was higher than those on conventional urethrography in this study. The mean stricture diameter was 5.6 ± 1.2 mm on SUG and 2.2 ± 0.7 mm on conventional urethrography. Ravikumar and colleagues¹⁰ reported that conventional urethrography and SUG had average stricture diameters of 0.9 mm and 1.1 mm, respectively with a mean difference of 0.2 mm ($P < 0.01$).

References

1. Choudhary S, Singh P, Sundar E, Kumar S, Sahai A. A comparison of sonourethrography and retrograde urethrography in evaluation of anterior urethral strictures. *ClinRadiol.* 2004; 59: 736-742.
2. McAninch J W, Laing F C, Jeffrey R B. Sonourethrography in the evaluation of urethral strictures: a preliminary report. *J Urology* 1988; 139:294-297.
3. Nnewi Latitude and Longitude. Available online from : <https://www.distance.to.com/coordinates/ng/newi-latitude longitude / history / 17712. html>. Assessed on 23 Jun 2017.
4. Dowsett D J, Kenny PA, Johnston RE. Basic projection X-ray imaging systems. In: *The Physics of Diagnostic Imaging*. 2nd ed. Hodder Arnold, London. 2006:228.
5. Okpala O C, Okafor C, Aronu M E. Synchronous retrograde and Micturating cysto- urethrography a modification. *AJOL* 2011; 2:28-31.
6. Morey AF, McAninch JW. Ultrasound evaluation of male urethra for assessment of urethral stricture. *J Clin Ultrasound* 1996; 24:473-479
7. Khan MB, Ahmood RM, Ghaffar A, Mahmood T. Role of sonourethrography in evaluation of anterior urethral stricture and its comparison with retrograde urethrography. *PAFMJ* 2006; 56:300-305.
8. Priyadarshi V, Singh M, Kumar V, Tiwari R, Gupta SK, Sehgal N. The role of sonourethrography in the evaluation of anterior urethral strictures: A correlation with retrograde urethrography. *Uro Today IntJ* 2012; 5:1-6
9. Nitin G, Deepak D, Anil M, Aneesh S, Rakesh K, Anant K. Urethral stricture assessment: A retrospective study evaluating urethral ultrasonography and conventional radiologic studies. *BJU int* 2006; 98:149-153
10. Ravikumar B R, Tejus C, Madappa K M, Prashant D, Dhayanand G S. A comparative study of ascending urethrogram and sonourethrography in the evaluation of stricture urethra. *International braz j urol* 2015; 41:388-392.
11. Akpayak I, Ani C, Dakum N, Ramyil V, Shuaibu S. Sonourethrography In: *The Evaluation Of Anterior Urethral Stricture*. *JWACS* 2012; 2:1-13.
12. Hatgaonkar A. Comparative study of sonourethrography and retrograde urethrography in evaluation of anterior male urethral strictures. *IJSS* 2014; 2:5-12.
13. Nzeh DA, Braimoh KT, Oyinloye. Comparison of Sonographic and Radiographic Urethrography in The Evaluation of The Male Urethra: A Preliminary Report. *WAJUS* 2006; 7:8-12.
14. Dola VNS, Konduru S, Ameeral A, Maharaj P, Sa B, Ramesh R, et al. Ascending urethrogram and sonourethrography in evaluation of male anterior urethra. *JAMMR* 2017; 22:1-9.