



## Abdominal pain in the female patient: A case of concurrent acute appendicitis and infected ovarian cyst

Kabir Musa Adamu<sup>1</sup>, Hauwa Musa Abdullahi<sup>2</sup>

<sup>1</sup>Department of Surgery, Aminu Kano Teaching Hospital/Bayero University Kano, Nigeria

<sup>2</sup>Department of Obstetrics and Gynaecology, Aminu Kano Teaching Hospital/Bayero University Kano, Nigeria

### Abstract

**Background:** Abdominal pain is a common presentation in women of child bearing age. It has a broad diagnosis that includes disorders of the gastrointestinal, gynaecological, vascular, urogenital, and pulmonary systems. It may be caused by infections, inflammatory, anatomic or neoplastic processes. Its management varies by aetiology, and accurate diagnosis is key to avoiding inappropriate treatment. In some rare instances, acute appendicitis has been shown to occur simultaneously with a variety of gynaecologic diseases, which can add to the diagnostic dilemma.

**Method:** We report a case of concurrent acute appendicitis and infected ovarian cyst in a 49 year old P6+4A6 who presented with recurrent abdominal pain for 4 years duration.

**Result:** She had oophorectomy and appendicectomy. She did well post operatively and was discharged to outpatient department after stitches removal.

**Conclusion:** Abdominal pain, being from various aetiology in women of child bearing age, detail history, thorough physical examination, and necessary imaging investigations need to be done to avoid misdiagnosis and inappropriate treatment.

Kew words: Acute abdomen, appendicitis, ovarian cyst

### Introduction

As general surgeons we are often asked to evaluate a woman of childbearing age with acute abdominal pain. The differential diagnosis must be expanded to include all gynaecologic and non-gynaecologic causes in order to reach a diagnosis with appropriate treatment. Some of the gynaecological disorders include pelvic inflammatory diseases, infected or ruptured ovarian cyst, degeneration of uterine fibroid, ectopic pregnancy, and threatened abortion. Non-gynaecological disorders may include acute appendicitis, acute cholecystitis, bowel obstruction, and perforated peptic ulcer disease.<sup>1</sup> Despite

improvement in imaging, at times it may still be difficult to differentiate between gynaecologic and non-gynaecologic causes of abdominal pain prior to surgical intervention.<sup>1</sup> All women of child bearing age should have either a serum or urine  $\beta$ -human chorionic gonadotropin ( $\beta$ -HCG) level as part of the initial diagnostic workup.<sup>1</sup> One study showed that female patients who began their menstrual period within seven days of presentation with abdominal pain were five times more likely to have pelvic inflammatory disease than acute appendicitis.<sup>2</sup> Acute appendicitis is the most common surgical emergency,<sup>3,4</sup> and is also the most common cause of non-gynaecological pelvic pain.<sup>5</sup> It has been shown to occur simultaneously with a variety of gynaecologic diseases including ovarian cyst, uterine fibroids, endometriosis and hydrosalpinx,<sup>6</sup> hence the misdiagnosis rate of acute appendicitis in women of reproductive age has increased over

Corresponding Author: Dr Hauwa Musa Abdullahi

Department of Obstetrics and Gynaecology,  
Aminu Kano Teaching Hospital/Bayero University Kano,  
Nigeria.

Email: drhauwa@yahoo.com Phone: +2348037005966

time.<sup>7</sup> We report a case of concurrent acute appendicitis and infected ovarian cyst in a 49 year old P6+4A6 who presented with recurrent abdominal pain for 4 years duration.

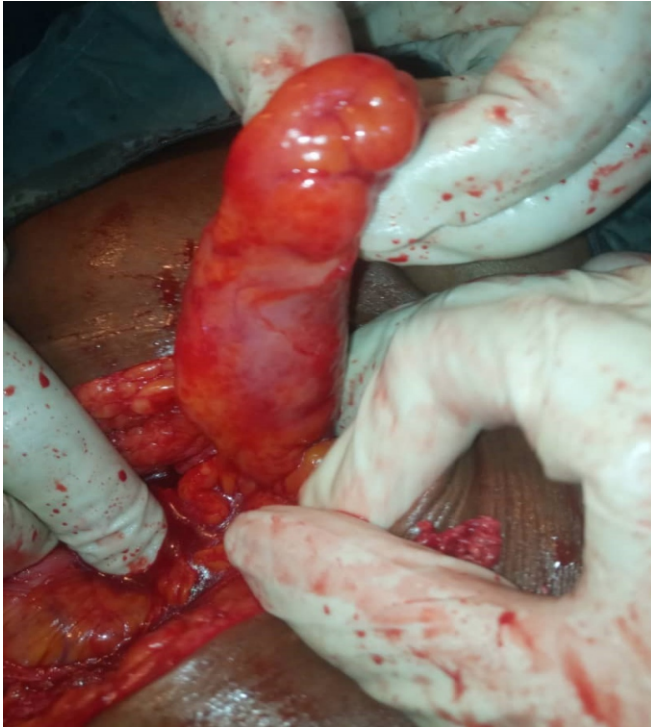

Fig 1: Inflamed appendix

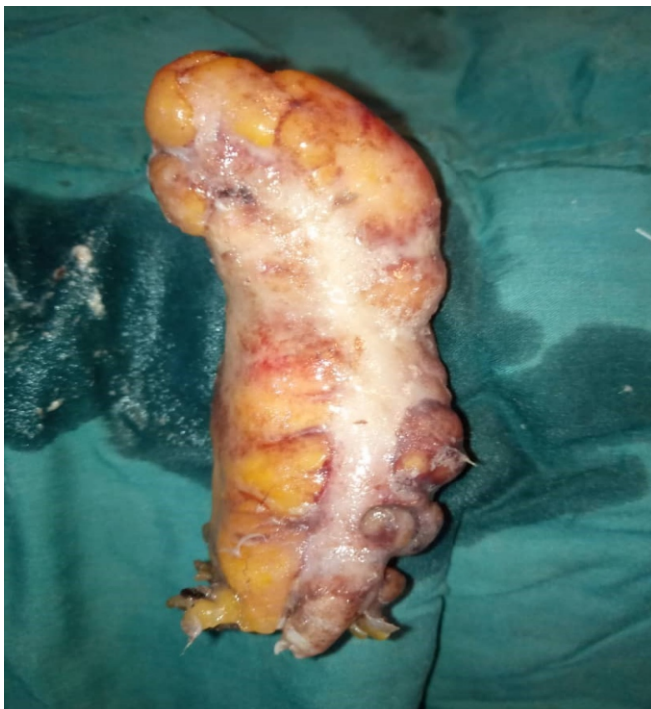

Fig 2: Excised appendix

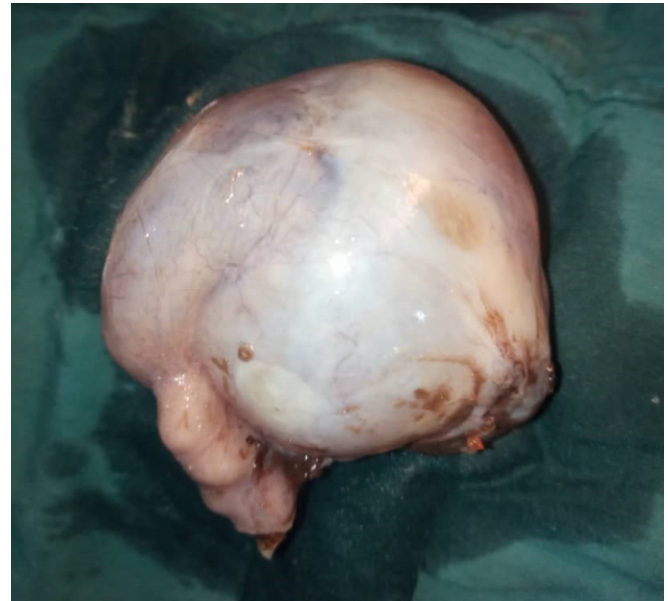


Fig 3: Excised ovarian cyst

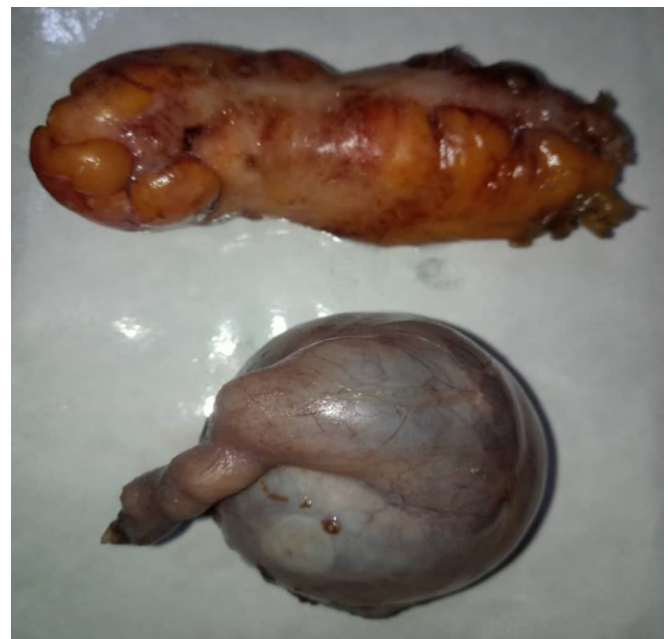

Fig 4: Excised appendix and ovarian cyst

The pathology reported revealed (1) Acute appendicitis with appendix measuring 7.5 x 0.7 cm with mucosal ulceration, transmural polymorph infiltrate often with serosal inflammatory response and fibrous adhesions. No fecolith found. (2) An ovarian cyst measuring 4.0 x 7.5 x 4.5 cm with thickened wall and abscess within it. No solid areas. The post operative period was uneventful and patient was kept on parenteral antibiotics, analgesics, intravenous fluid and monitoring of

vital signs. She did well and was discharged after stitches removal for follow-up in the outpatient department.

### Case report

A 49 year old P6+4A6 presented to our emergency unit with recurrent abdominal pain for 4 years duration. The pain was insidious in onset, initially dull in nature aggravated by eating food, relieved by taking analgesics and located in the right lower quadrant. It later became colicky, aggravated by activity and relieved by rest and same analgesics about one week before presentation to our hospital. There is associated mild headache with intermittent mild fever, anorexia and nausea. No other GIT symptoms. No genitourinary symptoms. No cardio-respiratory symptoms. Inserted intrauterine device (IUD) 4 years back. She was haemodynamically stable. Her physical examination was pertinent for right lower quadrant and suprapubic tenderness, negative for distention, guarding, rigidity or rebound. Her gynaecologic examination was negative for cervical motion and uterine or adnexal tenderness, and her last menstrual period was 12 days prior to presentation. There were normal findings on digital rectal examination. Laboratory investigations revealed a white blood cell count of  $11.5 \times 10^9 /L$  with 82% neutrophils and 12gm/dl haemoglobin. ESR was 30mm/hr. Her urinalysis was normal and her urine pregnancy test was negative. Transabdominal ultrasound (US) revealed a dilated appendix, measuring 8.5mm in diameter, and wall thickening consistent with acute appendicitis. Additional findings included an oval complex thick walled sonolucent cyst lesion with low level internal echoes seen in the right adnexa, measuring 42 x 71 x 41mm in dimension with a conclusion of complex ovarian cyst infected. E/U/Cr was within normal limit and grouping and cross matching of two units/pints of blood was also done. The surgical and gynaecologic teams, together, performed laparotomy after obtaining informed consent and anaesthetic clearance. Intraoperatively, the appendix appeared inflamed, without signs of necrosis, perforation, or abscess formation. The ovarian cyst measured approximately 8cm with no rupture. Appendicectomy and Oophorectomy were performed successfully (figs 1, 2, 3, 4).

### Discussion

Abdominal pain is a common presentation in women of child bearing age. It may be caused by infections, inflammatory, anatomic or neoplastic processes. In some rare instances, acute appendicitis has been shown to occur simultaneously with a variety of gynaecologic diseases, which can add to the diagnostic dilemma.<sup>1</sup> Our patient most likely has an ovarian cyst that has been giving her dull pain which is bearable for up to 4 years before it became infected, and developed acute appendicitis with colicky pain that warrant admission and treatment. Being of various aetiology in women of child bearing age, detail history, thorough physical examination, and necessary imaging investigations need to be done to avoid misdiagnosis and inappropriate treatment. The differential diagnosis includes but is not limited to acute appendicitis versus gynaecologic entities such as infected ovarian cyst, torsion of ovarian cyst, pelvic inflammatory disease, or ectopic pregnancy to name a few, keeping in mind that they may be concurrent with acute appendicitis or other surgical diseases such as acute cholecystitis, bowel obstruction, and perforated peptic ulcer disease to name a few.

Acute appendicitis carries a lifetime risk of 7% with a peak occurrence between the ages of 10 and 30 years and accounts for 27.5% of surgical emergencies.<sup>3,4</sup> The annual incidence in Nigeria is 22.1 – 49.8 new cases per 100,000. A history of periumbilical pain migrating to right lower quadrant (RLQ) is classic and has a positive predictive value of 90% in adults with acute appendicitis. Nausea, vomiting, diarrhoea and anorexia are also common.<sup>2,8</sup> Our patient had classical RLQ pain with anorexia and nausea. Physical examination likely reveals RLQ tenderness at McBurney's point. Rigidity, guarding or rebound tenderness may be elicited. Rovsing's sign, psoas sign and obturator sign may also be elicited on physical examination. If the appendix is located in the pelvis or there is pelvic abscess from perforated appendicitis, cervical motion tenderness will be positive. However, each of these findings can be found with infected ovarian cyst/ abscess but vaginal discharge should not be present in appendicitis, though undiagnosed sexually transmitted disease can coexist with appendicitis or any other abdominal pathology.



Fever and leukocytosis may be present, and have been reported in about one-third of adults with acute appendicitis.<sup>2</sup> Leukocytosis alone has low specificity, but elevated WBC count with neutrophilia and elevated C-reactive protein level has a sensitivity of 97 to 100%. Our patient had elevated WBC, neutrophilia and an elevated ESR (we could not assay C-reactive protein). Ultrasound scan (USS) showing non-compressible, non-peristaltic tubular structure arising from the base of the caecum measuring more than 6mm in diameter is used to aid in diagnosis.<sup>5,9</sup> An appendicolith may also cause acoustic shadowing on USS.<sup>9</sup> Computed tomography (CT) scan can also be used in aiding diagnosis where it can show periappendiceal fat stranding, an enlarged appendix that does not fill with contrast, and a caecal/appendiceal wall thickening.<sup>3,10,11</sup> Our patient had appendix diameter of 8.5 mm from USS examination. On histopathology, acute appendicitis is characterized by mucosal ulceration, transmural polymorph infiltrate often with serosal inflammatory response and fibrous adhesions which is demonstrated in the pathology slide of our patient's appendix. Appendectomy is the standard of care for uncomplicated appendicitis like the treatment we gave to our patient, but reported negative appendectomy rates can be as high as 25 % in adult women, higher than that in both men and children.<sup>2,8</sup> Appendectomy should be considered when no other definitive cause of abdominal pain is recognized.

Infected ovarian cyst or/tubo-ovarian abscess (IOC/TOA) is a serious complication of pelvic inflammatory disease (PID) occurring in approximately 5-34% of women with PID.<sup>12-15</sup> Typically occurs in women of reproductive age, most frequently in women aged 20-40.<sup>12,13,16</sup> Our patient age is within reproductive age and her last menstrual period (LMP) was 12 days before presentation for admission. A small percentage occurs in postmenopausal women.<sup>16,17</sup> As many as 60% of women are nulliparous.<sup>12</sup> Risk factors include multiple sexual partners, intrauterine device (IUD) use, low socioeconomic status, immunosuppression, and HIV.<sup>12-15,17</sup> Our patient has been with IUD for 4 years before presentation. Approximately two-thirds of TOA are unilateral, which may lead to misdiagnosis as acute

appendicitis when right sided.<sup>12-16</sup> It is a polymicrobial infection<sup>15,16</sup> and may be a result of non-gynaecology diseases, including appendicitis, diverticulitis, inflammatory bowel disease and surgery.<sup>16</sup> The symptoms of IOC are similar to that of appendicitis and include lower abdominal pain, nausea, anorexia, and diarrhea.<sup>12,14-17</sup> Fever and chills though unreliable in up to 50 % of patients may be present.<sup>13,15</sup> Our patient presented with some of these symptoms. Patients may also present with mucopurulent cervicovaginal discharge or vaginal bleeding,<sup>15</sup> and this should point the physician away from a diagnosis of appendicitis and toward a diagnosis of IOC/TOA.<sup>12,14,17</sup> Leukocytosis may be present but is not a reliable indicator of IOC/TOA,<sup>15</sup> seen in our patient too. On abdominal examination rebound tenderness or guarding may be elicited,<sup>12,17</sup> which were elicited on our patient. Cervical motion tenderness may be elicited.<sup>12,14,16</sup> Ultrasound scan (USS) is the diagnostic imaging of choice with a sensitivity of greater than 90 %.<sup>15,18</sup> While trans-abdominal USS provides a larger field of view in helping to identify adnexal masses, transvaginal USS may provide a more detailed view of pelvic anatomy and vasculature.<sup>14,18</sup> Trans-abdominal USS was used in the diagnosis of IOC in our patient. While CT scan may be indicated when the diagnosis is unclear,<sup>5,12,17</sup> MRI is used infrequently for cases where the diagnosis is uncertain.<sup>5</sup> Antibiotic therapy, with or without additional surgical or drainage procedures is the standard of care for IOC/TOA. Our patient had antibiotics and Oophorectomy.

### Conclusion

This case illustrates how acute appendicitis can occur concurrently with gynaecologic disorders like infected ovarian cyst. Detailed history, thorough physical examination and necessary imaging investigations need to be done to avoid misdiagnosis and inappropriate treatment. We were able to appropriately treat this patient with a multidisciplinary approach. Such an approach can help to prevent system failure and improve patient safety and outcomes.

### Financial support and sponsorship

Nil

**Conflicts of interest**

There are no conflicts of interest.

**References**

1. Boyd C, Riall TS. Unexpected gynaecologic findings during abdominal surgery. *Current problems in surgery*. 2012; 49(4):195-251.
2. Lewis FR, Holcroft JW, Boey J, Dunphy E. Appendicitis. A critical review of diagnosis and treatment in 1000 cases. *Archives of surgery*. 1975; 110(5):677-684.
3. Karam AR, Birjawi GA, Sidani CA, Haddad MC. Alternative diagnosis of acute appendicitis on helical CT with intravenous and rectal contrast. *Clinical Imaging*. 2007; 31(2):77-86.
4. Olusegun A. Acute appendicitis: Incidence and management in Nigeria. *Journal of the Obafemi Awolowo University Medical Students Association*. 2008; 14(1):66-70.
5. Vandermeer FQ, Wong-You-Cheong JJ. Imaging of acute pain. *Clinical Obstetrics and Gynaecology*. 2009; 52(1):2-20.
6. Song JY, Yordan E, Rotman C. Incidental appendectomy during endoscopic surgery. *Journal of the Society of Laparoendoscopic Surgeons*. 2009; 13(3):376-383.
7. Flum DR, Morris A, Koepsell T, Dellinger EP. Has misdiagnosis of appendicitis decreased over time? A population-based analysis. *Journal of the American Medical Association*. 2001; 286(14):1748-1753.
8. Lee SL, Ho HS. Acute appendicitis: Is there a difference between children and adults? *American Surgeon*. 2006; 72(5):409-413.
9. Patel SJ, Reede DL, Katz DS, Subramaniam R, Amorosa JK. Imaging the pregnant patient for nonobstetric conditions: Algorithms and radiation dose considerations. *Radiographics*. 2007; 27(6):1705-1722.
10. Eshed I, Halshtok O, Erlich Z, Guranda L, Hiller N, Apter S, et al. Differentiation between right tubo-ovarian abscess and appendicitis using CT: A diagnostic challenge. *Clinical Radiology*. 2011; 66(11):1030-1035.
11. Rao PM, Rhea JT, Novelline RA. Sensitivity and specificity of the individual CT signs of appendicitis: Experience with 200 helical appendiceal CT examinations. *Journal of Computer Assisted Tomography*. 1997; 21(5):686-692.
12. Rosen M, Breitkopf D, Waud K. Tubo-ovarian abscess management options for women who desire fertility. *Obstetrical and Gynaecological Survey*. 2009; 64(10):681-689.
13. Goharkhay N, Verma U, Maggiorotto F. Comparison of CT- or Ultrasound-guided drainage with concomitant intravenous antibiotics Vs Intravenous antibiotics alone in the management of tubo-ovarian abscess. *Ultrasound in Obstetrics and Gynaecology*. 2007; 29(1):65-69.
14. Granberg S, Gjelland K, Ekerhovd E. The management of pelvic abscess. *Best practice and Research: Clinical Obstetrics and Gynaecology*. 2009; 23(5):667-678.
15. Landers DV, Sweet RL. Tubo-ovarian abscess: Contemporary approach to management. *Reviews of Infectious Diseases*. 1983; 5(5):876-884.
16. Gjelland K, Ekerhovd E, Granberg S. Transvaginal ultrasound-guided aspiration for Treatment of tubo-ovarian abscess: A study of 302 cases. *American Journal of Obstetrics and Gynaecology*. 2005; 193(4):1323-1330.
17. Mirhashemi R, Schoell WM, Estape R, Angioli R, Averette HE. Trends in the management of pelvic abscess. *Journal of American College of Surgeons*. 1999; 188(5):567-572.
18. Lee DC, Swaminathan AK. Sensitivity of ultrasound for the diagnosis of tubo-ovarian abscess: A case report and literature review. *Journal of Emergency Medicine*. 2011; 40(2):170-175.