



Retinal changes among pre-eclamptic patients in University of Benin Teaching Hospital, Benin, Nigeria

Uwagboe PN^{*}, Ebeigbe JA¹, Uwagboe CU²

¹Department of Optometry, University of Benin, Benin City, Edo State, Nigeria

²Department of Obstetrics and Gynecology, University of Benin Teaching Hospital, Benin City, Edo State, Nigeria

Abstract

Background: Preeclampsia is one of the hypertensive disorders in pregnancy that contributes significantly to maternal and fetal morbidity and mortality, with the impact felt more in developing countries. It is characterized by endothelial dysfunction and vasospasm of vessels which can be observed by an ocular fundal examination. The aim of this study was to determine the ocular fundus findings of women with preeclampsia.

Methods: This was a cross-sectional study, carried out at the University of Benin Teaching Hospital involving a total of 220 pregnant women. The women were divided into two groups of 110 pregnant women (A&B). Their Age and Gestational age was cross-matched and retinopathy graded according to Keith and Wagner classification. Group A was made up of Preeclamptic women and Group B was made up of healthy pregnant women. Visual acuity was measured using Snellens' chart, and the fundus was examined with direct ophthalmoscope.

Results: This showed that the retinal changes observed in the preeclamptic women were associated with their age ($P = 0.009$), gestational age ($P = 0.044$), blood pressure ($P = 0.001$), Proteinuria ($P = 0.001$), Severity of the disease ($P = 0.001$), visual acuity ($P = 0.035$) as well as with the visual symptoms ($P = 0.001$) but not statistically significant with the gravida ($P = 0.799$).

Conclusion: Our study highlights the importance of timely ophthalmoscopy which helps to assess severity of disease (pre-eclampsia) which affects the decision of induction of delivery to predict and prevent possible complications which in turn immensely helps in judicious management of disease. Also, the study revealed that preeclamptic women who are multigravida are more likely to have retinopathy than primigravida.

Keywords: Eclampsia, hypertensive retinopathy, preeclampsia, retinal changes, retinal detachment.

Introduction

Hypertension is a common condition in pregnancy. It could be chronic (pre-existing) or gestational hypertension. Gestational hypertension is hypertension without proteinuria. Preeclampsia is associated with hypertension, proteinuria and

generalized edema the progression of preeclampsia with convulsion in addition, leads to a condition termed eclampsia.¹ Preeclampsia has been defined according to the American College of Obstetricians and Gynecologists (ACOG)² as the development of hypertension with a systolic blood pressure of 140 mm/Hg or higher or a diastolic blood pressure of 90 mm/Hg or higher with proteinuria occurring after 20 weeks of gestation in a woman with previously normotensive and non-proteinuric patients (ACOG-2002).² Risk factors for preeclampsia include previous history of preeclampsia, nulliparity, older women, twin

Corresponding Author: Dr. Precious N. Uwagboe

Department of Optometry,
University of Benin, Benin City,
Edo State, Nigeria
E-mail: precious.uwagboe@uniben.edu

gestation, and teenage pregnancy, and preexisting hypertension, family history of hypertensive disease, obesity, chronic renal disease and antiphospholipid syndrome.

Vascular narrowing is the primary response of the retinal vasculature to systemic arterial hypertension. An increase in blood pressure causes focal or diffuse vasoconstriction. In addition, extravasation of fluid to the extravascular spaces occurs as a result of increased vascular permeability. Resultant retinal changes may manifest as decreased artery to vein ratio, cotton wool spots, hemorrhages, Elsching spots and serous retinal detachments.³ Retinal arteries narrowing can be demonstrated in about 50% of uncomplicated pregnancies with physiologic increase in blood pressure. This narrowing is functional and disappears with the termination of pregnancy.³ The complications of preeclampsia extend to involve multiple systems and organs, the eye and visual system are of no exception. Visual symptoms concern up to 25% of patients with severe preeclampsia and 50% of patients with eclampsia.⁴ Pre-eclampsia/eclampsia has various ocular manifestations. Blurred vision is the most common visual complaint. Focal or generalized arteriolar narrowing is the most common ocular finding in preeclampsia/eclampsia syndrome. Other ocular manifestations include photopsia, visual field defects, and sudden inability to focus, and in severe cases, complete blindness.⁴

Pre-eclampsia is a potentially life-threatening multisystemic disorder. It contributes to maternal and perinatal mortality and morbidity worldwide.⁵ However, in Nigeria eclampsia incidence lies in the range of 0.3 per 1000 deliveries in Calabar (Cross River State) to as high as 9 per 100 deliveries in Birnin Kudu (Jigawa State).⁶

Tadin et al⁷ from Croatia have reported 45% of retinal changes in their study of 40 patients with pre-eclampsia and the degree of retinopathy was directly proportional to severity of pre-eclampsia. Out of 275 cases of pre-eclampsia and 125 cases of eclampsia studied, Reddy⁸ from India has reported retinal changes in 53.4% preeclampsia and in 71.2% in eclampsia patients (over all 59%, 236 out of 400) and it was concluded that retinal changes were significantly more in patients with severe hypertension. However, there is paucity of

information on the presence of retinal changes among pre-eclamptic women in our locality, this prompted this work. The study also aimed at finding out if there is any association between retinal changes and age, blood pressure, proteinuria and severity of the disease.

Materials and Methods

The study was a cross-sectional, observational study carried out at the University of Benin Teaching Hospital Benin City. The study population was divided into two groups A and B. Group A was made up of 110 women who were diagnosed with preeclampsia and admitted in the obstetric ward of University of Benin Teaching Hospital and Group B consist of 110 healthy pregnant women who did not have hypertension and proteinuria and were undergoing routine antenatal checkup. The age and gestational age of both groups were cross-matched.

Inclusion Criteria: Patient diagnosed with preeclampsia, pregnancy greater than 20 week, and pregnant women with significant hypertension and proteinuria.

Exclusion Criteria: Patient who had pre-existing diabetes, those who had pre-existing hypertension, patients with renal disease, patients with hazy media which will not permit fundus visualization

Description of procedure

For both groups, history for any eye symptoms was taken, the age and gestational age were matched, and visual acuity was carried out at 6m using the Snellen's chart. Anterior segment was examined with pen light under dim illumination. Both pupils were dilated with 1% tropicamide eye drops and the fundus was examined with direct ophthalmoscope in a semi dark room. Hypertensive retinopathy changes seen in right or left or both eyes, was taken as positive findings in that patient. The retinal changes (hypertensive retinopathy) was graded according to Keith Wagener classification of Hypertensive Retinopathy.⁹

Grade I: Mild generalized arterial attenuation, particularly of small branches;

Grade II: More severe Grade I+ focal arteriolar attenuation;

Grade III: Grade II+ hemorrhages, hard exudates, cotton wool spots;

Grade IV: Grade III +optic disc swelling (papilledema).

Proteinuria was tested using dipstick method and was graded as += 30 mg/dL, ++= 100 mg/dL, +++= 300 mg/dL and ++++ \geq 2000 mg/dL as provided by manufacturer. Age, parity, gravidity, blood pressure, was noted from the case records. All the findings were noted on a data extraction sheet.

The severity of preeclampsia was classified into:

- **Mild preeclampsia:** BP >140/90mmHg, and proteinuria+.
- **Severe preeclampsia:** BP >160/110mmHg, proteinuria++, headache, cerebral or visual disturbances, and epigastric pain.
- **Eclampsia:** Severe preeclampsia and convulsions.¹⁰

Table I: Age, parity and gestational age of preeclamptic women

<i>Parameter</i>	<i>Frequency (No)</i>	<i>Percentage (%)</i>
<i>Age(years)</i>		
21 – 25	2	1.8
26 – 30	32	29.1
31 – 35	39	35.5
36 – 40	28	25.5
41 – 45	9	8.2
Total	110	100
<i>Gestational age (weeks)</i>		
26 – 29	23	20.9
30 – 33	55	50.0
34 – 37	32	29.1
Total	110	100
<i>Gravidity</i>		
Primi	59	53.6
Multi	49	44.5
Grand Multi	2	1.8
Total	110	100

The above table revealed that most of the patients were between the ages of 31 and 35 years (35.5%) followed by patients between the ages of 26-30 years (29.1%) and were first-time pregnant and were between the 30th and 33rd week of gestation.

Ethics and informed consent

The study protocol adhered according to the tenet of the declaration of Helsinki on the world medical association regarding scientific research on humans. Ethical clearance was obtained from university of Benin Teaching Hospital research and ethics committee and informed consent was obtained from the subjects after detailed explanation on the nature and aim of the study.

Statistical package

Statistical analysis was performed using IBM statistical package for social science (SPSS) version 23.0.

Chi-square test was used to determine the association between the retinal changes and blood pressure, proteinuria, and severity of preeclampsia. P value < 0.05 was taken as significant

Table II: Visual acuity, blood pressure, proteinuria and severity of the disease among the preeclamptic women

<i>Parameter</i>	<i>Frequency (No)</i>	<i>Percentage (%)</i>
<i>Snellen visual acuity</i>		
6/18 – 6/12	6	5.5
6/9 – 6/5	104	94.5
<i>Blood Pressure (mmHg)</i>		
< 160/100	60	54.5
= 160/100	50	45.5
<i>Proteinuria</i>		
+		
++	77	70.0
+++	21	19.1
<i>Severity of the disease</i>		
Mild preeclampsia		
Severe preeclampsia	77	70.0
Eclamptic	21	19.1
	12	10.9

Most of the patients had visual acuities between 6/9 and 6/5 (94.5%), blood pressure less than 160/100mmHg (54.5%) and mild preeclampsia (70%).

Table III: Association of retinopathy with different variables recorded in the subject with preeclampsia

<i>Parameter</i>	<i>Retinal changes</i>				<i>Total</i>	<i>P</i>
	Nil change	Grade 1	Grade 2	Grade 3		
<i>Age(years)</i>						
21 – 25	2	0	0	0	2	0.009
26 – 30	30	0	1	1	32	
31 – 35	27	6	2	4	39	
36 – 40	21	2	0	5	28	
41 – 45	4	0	0	5	9	
<i>Gestational age (weeks)</i>						
26 – 29	14	2	0	7	23	0.044
30 – 33	43	3	1	8	55	
34 – 37	27	3	2	0	32	
<i>Blood pressure (mmHg)</i>						
< 160/100	55	4	1	0	60	0.001
> 160/100	29	4	2	15	50	
<i>Proteinuria</i>						
+	70	6	1	0	77	0.001
++	14	2	1	4	21	
+++	0	0	1	11	12	
<i>Severity of the disease</i>						
Mild	70	6	1	0	77	0.001
Severe	14	2	1	4	21	
Eclampsia	0	0	1	11	12	
<i>Gravida</i>						
Primi	48	4	1	6	59	0.799
Multi	34	4	2	9	49	
Grand Multi	2	0	0	0	2	
<i>Visual symptoms</i>						
Blurred vision only	9	1	0	6	16	0.001
Diplopia and blurred vision	0	0	1	0	1	
Headache only	24	3	0	1	28	
Headache and blurred vision	0	0	1	7	8	
Headache, diplopia and blurred vision	0	0	0	1	1	
<i>Visual acuity</i>						
6/18 – 6/12	2	1	0	3	6	0.035
6/9 – 6/5	82	7	3	12	104	

The outcome of the test showed that the retinal changes observed in the patients was associated with their age ($P = 0.009$), gestational age ($P = 0.044$), blood pressure ($P = 0.001$), Proteinuria ($P = 0.001$), Severity of the disease ($P = 0.001$), visual acuity ($P = 0.035$) as well as with the visual symptoms ($P = 0.001$) but not statistically significant with the gravida ($P = 0.799$). Retinal changes (hypertensive retinopathy) were noted in 26 (23.6%) patients in Group A however no retinal changes were found in group B.

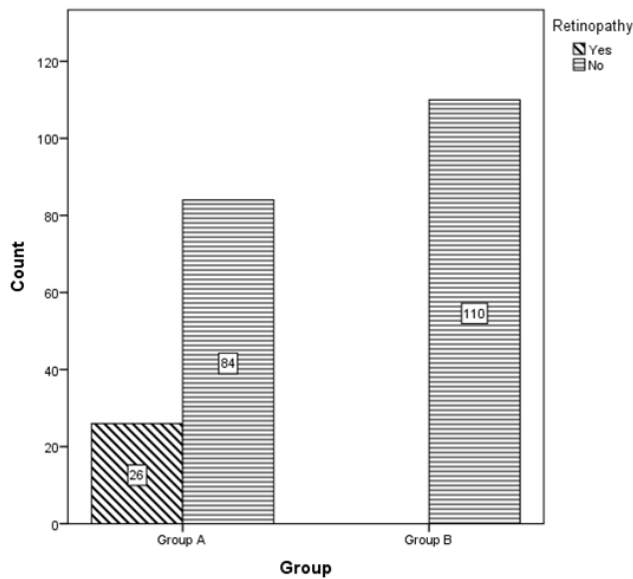


Figure I: Distribution of retinal changes among subjects and control

Results

The 220 women enrolled in this study were divided into two groups. The mean age of the patients in group A was 33.98 ± 4.79 years. While mean age in group B was 33.47 ± 4.72 years the gestational age ranged between 26 and 37 weeks. For group A: Fifty-nine (53.6%) were primigravidae (first time pregnant), 49 (44.5%) were multigravidae (2-4 pregnancies) and 2 (1.8%) were grand-multigravida (5 or more pregnancies). For Group B: forty-two (38.2%) were primigravidae, forty-one (37.3%) were multigravidae while twenty-seven (24.5%) were grand-multigravida.

Mild preeclampsia occurred in 77 (70%) while 21 (19.1%) had severe preeclampsia. Eclampsia occurred in 12 (10.9%) of the women in group A.

Discussion

Preeclampsia is a multisystemic hypertensive disorder that affects 3-5% of pregnancies and is one of the major causes of maternal mortality especially in developing countries. Our study revealed that 26 (23.6%) of the pre-eclamptic women had retinal changes. This is in agreement with the study done by Rasidi¹¹ who reported 21.5% from Malaysia, but different from the Ranjan¹² and Javadekar¹³ work who reported 40% and 42% retinal changes in India respectively. The lower percentage of retinal changes seen in our study could be attributed to the fact that that pregnant women in and around Benin

being admitted into University of Benin Teaching Hospital underwent routine antenatal checkups and treatment for Hypertension if any is being instituted. Our present study showed that patients with high blood pressure ($>160/100$ mmHg) have a higher chance of having retinal changes. This finding was in agreement with the finding of Tadin et al⁷ and Reddy et al.⁸ It however, contradicted the findings of Gupta et al¹⁴ who reported that severity of retinopathy might be independent of systemic blood pressure. The retinal changes found in our work were-arteriolar narrowing, cotton wool spots, hemorrhages. There was no case of serous retinal detachment. Changes in the retinal arterioles and retinal hemorrhages may indicate similar changes in the placenta microcirculation.¹⁴ Since the foetus well-being depends on the placenta microcirculation, ophthalmoscopic evaluation of mother's fundus may give a clue to similar micro circulation changes in the placenta and indirectly to the foetus wellbeing. Fundus examination in patients with preeclampsia is an important clinical evaluation to predict adverse foetal outcomes.

Also, Grade I and II retinal changes were found in patients with blood pressure $160/100$ mmHg while Grade III was seen in patients with blood pressure $>160/100$ mmHg. This finding is in agreement with the work done by Shukla and Prasad et al,¹⁵ and has shown that the higher the blood pressure the more severe the retinal changes.

Proteinuria is an important sign of preeclampsia. The minimum criteria for the diagnosis of preeclampsia are hypertension and proteinuria which may be minimal or severe; it ranges from +1 to +4. Our study showed that women with more severe proteinuria (+3) had more severe retinal changes (see table 3). This finding is in accordance with the work of Shukla et al¹⁵ which concluded that as the severity of albuminuria increases, the severity of retinal changes also increases.

Conclusion

Fundoscopy is a simple, non-invasive, safe and reliable procedure to interpret the vascular changes. This study revealed that retinal changes were seen more in patients with severe hypertension, severe proteinuria and severity of the disease. This showed that the higher the blood pressure and the grade of proteinuria the more severe the grades of

retinopathy.

It also revealed that Grade III hypertensive retinopathy was the most common retinal findings observed amongst women with preeclampsia.

There is the need for prompt referral of pregnant women with retinal changes by the eye care practitioner to the obstetricians for proper management. Also there is need to incorporate fundus examination in patients with preeclampsia and eclampsia and refer them for ophthalmic care accordingly.

References

1. Adelberg, D.A., Valluri, S., Curtis, R.S. and Olk, R.J... Diagnostic indocyanine green angiography in preeclampsia. *American Journal of Ophthalmology* (1996) 122:672-677
2. ACOG Practice Bulletin Committee. Diagnosis and management of preeclampsia and eclampsia. *International Journal of Gynecology & Obstetrics*. (2002)77:67-175
3. Gupta, A., Kaliaperumal, S., Setia, S., Suchi, S.T. and Rao, V.A. Retinopathy in preeclampsia: Association with birth weight and uric acid level. *Retina*. (2008) 2:1104–1110.
4. Mussey, R.D., Mundell B.J. Retinal examinations: A guide in the management of the toxic hypertensive syndrome of pregnancy. *American Journal of Obstetrics & Gynecology*; (1939) 37:30-36.
5. McClure, E. M., Saleem, S., Pasha, O. and Goldenberg, R. L. Stillbirth in developing countries: A review of causes, risk factors and prevention strategies. *Journal of Maternal-Fetal and Neonatal Medicine*. (2009) 22(3):183-190.
6. Tukur, J., Umar B.A., Rabi U Patterns of Eclampsia in a tertiary Health facility situated in a semi –Rural town in Northern Nigeria. *Annals of African Medicine* (2007).6(4)164-167
7. Tadin, I., Bojic, L., Mimica, M, Karelovic. and Dogas Z. Hypertensive retinopathy and pre eclampsia. *Collegium Antropologicum*. (2011)25:77-81.
8. Reddy, S.C, Nalliah, S., George, S. Who TS. Fundus changes in pregnancy induced hypertension. *International Journal of Ophthalmology* (2012). 5:694-697
9. Keith, N.M., Wagener, H.P and Barker N.W Some different types of essential hypertension: their course and their prognosis. *American Journal of Medical Science*; (1939) 197:332-343.
10. Krishna, M Clinical guidelines in obstetrics for state of Perak. Department of obstetrics and gynecology, Hospital Ipoh, Ministry of Health Malaysia. (2002) pg 69
11. Rasdi, A.R, Nik-Ahmad Zuky, N.L., Bakiah, S. and Shastriah, I Hypertensive retinopathy and visual outcome in hypertensive disorders in pregnancy. *Medical Journal of Malaysia*. (2011). 66:42-47.
12. Ranjan, R., Sinha, S. and Seth, S Fundus changes and fetal outcomes in pregnancy induced hypertension: An observational study. *International Journal of Environmental and Science Education*. (2014). 2:6-9
13. Javadekar, S.D., Javadekar, D.P., Joshi, K. and Khatiwala R Fundoscopic changes in pregnant mother with hypertension complicating pregnancy and various parameters of foetus. *International Journal of Recent Trends Science and Technology*. (2013) 7:110-3.
14. Prasad, G.N. and Shukla B.K. Retinal changes in eclampsia and pre-eclampsia. *Journal of the American Medical*. (1976). 66:8-10.

Acknowledgment: Authors would like to thank individuals who participated in the study.

Funding: No funding sources

Conflict of interest: None declared