



## Placenta percreta with attachment to the small bowel and spontaneous uterine rupture: A case report

Attah Raphael Avidime

Department of Obstetrics and Gynaecology, Bayero University/Aminu Kano Teaching Hospital, Kano, Nigeria.

### Abstract

Placenta percreta is quite an uncommon and potentially dangerous condition in pregnancy, which could lead to morbidity and mortality. It can adhere or invade the structure(s) adjacent to the uterus including the urinary bladder, rectum, and small intestine. The invasion of bladder is common but that of small bowel is extremely rare. This report presents a case of placenta percreta with small bowel attachment and spontaneous uterine rupture at 35 weeks gestation in a pregnancy conceived through invitro fertilization with history of previous myomectomy which was managed without intestinal resection.

### Introduction

Adherent placenta can be classified according to its degree of invasion into the myometrium.<sup>1</sup> When the chorionic villi are attached to the myometrium without invasion but placental separation is difficult, it is classified as placenta accreta. When partial myometrial invasion occurs, it is classified as placenta increta. When the placenta penetrates completely through the full thickness of the myometrium, and possibly involve adjacent structures, it is classified as placenta percreta. Predisposing risk factors include uterine scarring usually due to previous cesarean sections, endometrial curettage, previous placental retention requiring manual removal, and endometriosis.<sup>2</sup>

The placental trophoblastic tissue does not normally invade the myometrium, as they are separated by the decidual plate. The deeper penetration into the myometrium is prevented by a tough part of tissue layer known as Nitabuch's layer.<sup>3</sup> In some cases, this preventive layer is absent and the placentation gets deeper into the myometrium resulting in a condition known as adherent placenta.<sup>4</sup> Placenta percreta is a

type of adherent placenta, and invasion of small bowel is one of the rarest complications of placenta percreta.<sup>5</sup>

Abnormally adherent placenta is attributed to complete or partial absence of the decidual plate, allowing abnormal penetration of trophoblastic tissue into the myometrium. Placenta percreta, the severe form of abnormal placental adherence, rarely occurs but can result in fatal outcome such as uterine rupture and hemoperitoneum.<sup>2</sup>

The incidence of placenta percreta with invasion of adjacent organs is low, but the most frequently affected pelvic structure is the urinary bladder. Placenta percreta is fatal because of the high risk of complications from secondary uterine rupture or adjacent organ involvement, and because of late diagnosis, often only discovered at the time of delivery. Complications occur when the anatomy of the lower uterine segment is distorted; and the massive blood vessels that often supply the placenta from the pelvic side wall are torn during manipulation, resulting in severe hemorrhage.<sup>3</sup>

### Case Report

We report this case of a 48year old primigravida at estimated gestational age of 35weeks who suddenly started having abdominal pain with weakness of the body of 5hours duration, and presented to this private hospital. She was said to have collapsed on her way to the hospital. She was a booked patient of

Corresponding Author: Dr. Attah Raphael Avidime

Department of Obstetrics and Gynaecology,  
Bayero University/Aminu Kano Teaching Hospital,  
PMB 3452, Kano State, Nigeria.

E-mail: attahraph@yahoo.com, Phone: +2348060296224

this hospital. index pregnancy was conceived through invitro-fertilization after 19years of primary infertility. She has had myomectomy done in another private hospital about 6years before this pregnancy. Ultrasound scan done at 9weeks showed a singleton live fetus with expected date of delivery to be 24<sup>th</sup> June 2021.

On examination she was found to be in shock with cold extremities, she was severely pale, anicteric, acyanosed. Her pulse rate was 120 per minute small volume pulse and blood pressure was 70/50mmHg. investigations done were as follows; packed cell volume 20%, blood group O Rhesus Positive, retroviral screening and HBsAg were non-reactive. Ultrasound scan was done which showed a singleton live fetus at EGA of 35weeks with haemoperitoneum. A diagnosis of spontaneous uterine rupture was made and plan was for immediate laparotomy. Resuscitation was commenced and four pints of O positive blood were made available.

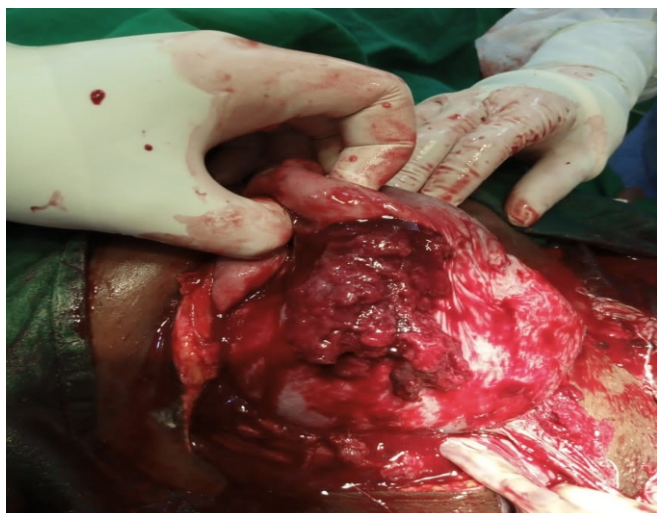


Figure 1. Placenta percreta with attachment to the small intestine

Intra-operative findings were haemoperitoneum of about 2litres, loops of intestine adherent to the fundus of the uterus with rupture at the fundus and placenta attached to the serosa of the small intestine. Baby was delivered through a lower uterine segment transverse incision, part of the placenta attached to the serosa of the small intestine was carefully separated and haemostasis secured. Uterine repair was done and bilateral tubal ligation. She had a male baby weighing 2.7kg, Apgar score of 6 and 7 in 1 and

5 minutes respectively. Baby was resuscitated and did well. Thereafter she was transfused with 4 pints of blood and maintained an uneventful postoperative recovery. Mother and baby were discharged after 6 days of admission. Hysterectomy was not done in this case because the placenta was carefully separated from the uterus and the small intestine. There was no need for intestinal resection and anastomosis since the attachment was only on the serosa of the small bowel.

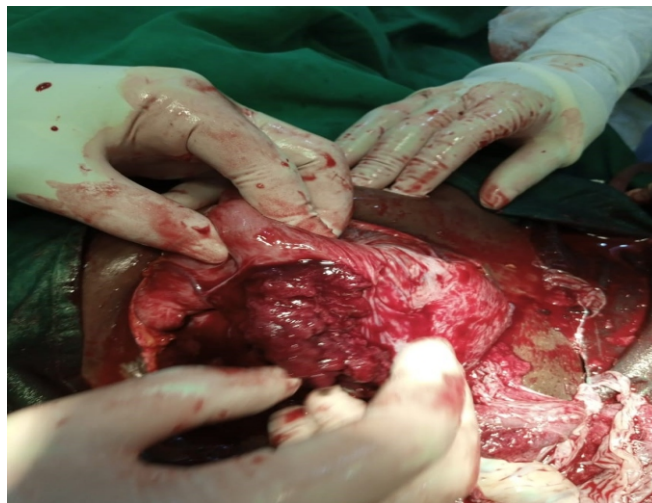

Figure 2. Placenta percreta with uterine rupture

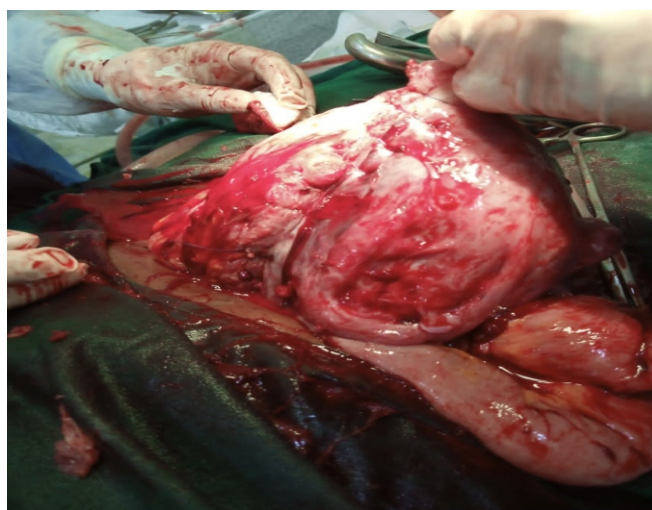

Figure 3. Repaired uterus

### Discussion

Placenta percreta with or without adherence to adjacent visceral organs is an important cause of both fetal and maternal morbidity and mortality. The risk factors for placenta percreta include previous

cesarean section, previous myomectomy, advanced maternal age, multiparity, and history of endometrial curettage.<sup>4</sup> In this case report the patient had previous history of myomectomy and conceived this pregnancy through invitro fertilization and embryo transfer. The incidence of adherent placenta has been found to be on the increase in the past few years, probably due to increase in the incidence of cesarean section and myomectomy.<sup>4</sup> There are only few cases of placental adherence to small bowel reported in the literature, whereas patients having urinary bladder wall invasion are more common.<sup>6</sup> This patient had placenta percreta with adherence to the serosa of the small intestine which is rare.

Uterine rupture, a life-threatening complication, occurs in approximately 14% of patients with placenta percreta, before, during, or after labour.<sup>1,7</sup> This patient was found to have uterine rupture at 35 weeks of gestation with intraoperative finding of haemoperitoneum of about 2litres.

Early diagnosis of this condition in the antenatal period is important in formulating a management plan to decrease maternal morbidity or maternal/fetal mortality. The diagnosis can be made by ultrasonography and magnetic resonance (MR) imaging. The findings on ultrasonography include the absence of normally apparent retroplacental hypoechoic line as an indication of placental adherence. In cases of bladder invasion, placenta may be seen indenting upon the bladder or protruding into it. In cases of bowel invasion, the gut loops may be seen adherent to placenta which may also result in bowel obstruction. The presence of an increasing number of lacunae in the placenta has also been shown to be a good predictor of adherent placenta on sonography. Unfortunately, the condition in the present case was not diagnosed on the prenatal ultrasonography. MRI imaging is relatively more specific and sensitive than ultrasonography in the diagnosis of various types of adherent placenta.<sup>8,9</sup>

The placenta percreta may result in a morbid obstetric hemorrhage and definitive management plan is to be kept ready to reduce it. The preferred management in cases of placental adherence includes a timely cesarean section with hysterectomy. In cases of bladder invasion, sometimes there is a need for partial cystectomy.

When the bowel is involved, it may result in intestinal obstruction. It is frequently managed by bowel resection and anastomosis but that predisposes to further adhesions.<sup>3,10</sup> Uterine repair and careful separation of the placenta from the uterus and the serosa of the small intestine was done in this case. Hysterectomy was not done, because the uterine rupture was small and easily repaired and the placenta was carefully separated. There was no need for any resection and anastomosis because the placenta did not invade the intestinal lumen, as it was attached on the serosa of the small intestine.

### Conclusion

Placenta percreta with attachment to the bowel is a rare occurrence, however when it occurs there is usually a previous history of uterine scar from either a caesarean section or myomectomy. Uterine rupture is frequently associated with this condition as found in this case report.

### References

1. Fox H, Sebire N. Pathology of the Placenta. Philadelphia, PA: Saunders Elsevier; 2007.
2. Clement PB, Young RH. Atlas of Gynecologic Surgical Pathology. Philadelphia, PA: Saunders Elsevier; 2014.
3. Go Eun Bae, Gun Yoon, Hyun-Soo Kim. Placenta percreta with small bowel invasion: unusual presentation of abnormal placental adherence Int J Clin Exp Pathol 2016;9(7):7237-7243.
4. Cimona Lyn Saldanha, Insha Khan, Mohd Ilyas. Placental Adherence to Small Bowel: An Uncommon Appearance of Placenta Percreta; Managed Without Intestinal Resection. Acta Medica International 5(1), 2018. DOI:10.4103/ami.ami\_72.
5. Goh WA, Zalud I. Placenta accreta: Diagnosis, management and the molecular biology of the morbidly adherent placenta. J Matern Fetal Neonatal Med 2016; 29:1795-800.
6. Smith ZL, Sehgal SS, Van Arsdalen KN, Goldstein IS. Placenta percreta with invasion into the urinary bladder. Urol Case Rep 2014; 2:31-7.
7. Esmans A, Gerris J, Corthout E, Verdonk P, Declercq S. Placenta percreta causing rupture of

- an unscarred uterus at the end of the first trimester of pregnancy: case report. *Hum Reprod* 2004; 19: 2401-2403.
8. American College of Obstetrics and Gynecologists. Placenta accreta. Committee Opinion No. 529. *Obstet Gynecol.* 2012 (Reaffirmed 2017); 120:207-11.
  9. Baughman WC, Corteville JE, Shah RR. Placenta accreta: Spectrum of US and MR imaging findings. *Radiographics* 2008; 28:1905-16.
  10. Karayalçın R, Özcan S, Özyer Ş, Mollamahmutoğlu L, Danışman N. Emergency peripartum hysterectomy. *Arch Gynecol. Obstet* 2011; 283:723-7.