



CHEMOTHERAPY-INDUCED ISOLATED RIGHT PAN-RETINAL ATROPHY

¹Etim, Bassey Archibong; ²Megbelayin, Emmanuel Olu

¹Department of Ophthalmology, Faculty of Medicine, University of Calabar, Nigeria

²Department of Ophthalmology, Faculty of Clinical Sciences, University of Uyo, Nigeria

ABSTRACT

A 51-year-old man, known diabetic and hypertensive, had 7 cycles of combined Rituximab, Fludarabine Phosphate and Cyclophosphamide subsequently developed defective vision in right eye. There was no complaint of visual impairment prior to systemic administration of cytotoxics. Best corrected visual acuity was Right Eye: 6/18 and Left Eye: 6/6. Right eye showed a dull-looking retina with generalised narrowing of retinal arterioles. Retinal veins showed normal calibre. Macular was thinned with retinal pigment epithelial changes.

Key words: Rituximab, Fludarabine Phosphate, Cyclophosphamide, retinal atrophy

INTRODUCTION

Topically applied ocular medications could be sufficiently absorbed to inflict untoward systemic consequences.¹⁻⁴ Timolol, a non-selective beta blocker is capable of eliciting severe asthmatic attacks in susceptible individuals. Timolol absorption is via nasal mucosa to systemic circulation. On another hand, systemically administered medications could through ophthalmic and ciliary arteries reach ocular tissues to unleash lethal effects. For instance chloroquine and its derivative, hydroxychloroquine sulphate, which have been useful in treating malaria and in larger doses, collagen-vascular disease, cause a cumulative dose-related pigmentary retinopathy.^{5,6} Mechanisms of action include inhibition of critical enzymes and interference with the metabolic functions of Retinal Pigment Epithelium (RPE) and photoreceptors. Both drugs apparently have a selective affinity for melanin, so they get

concentrated in RPE and uveal tissue and are retained for long periods, even after their usage is stopped.

Other drugs have been reported to have varied effects on different ocular tissues. Cisplatin, Camustine, Phenothiazide, and Chlorpromazine are associated with disruption of RPE.⁷ Aminoglycoside, Interferon, Ergot derivatives and Nicotinic acid are associated with retinal vascular damage. Tamoxifen, Talc⁸, Canthaxanthine, Nitrofurantoin⁹ and Methoxyflurane are associated with crystalline retinopathy. Rifabutin and Cidofovir^{10,11} have been linked with uveitis.

With discovery of new drugs, it is expected that there would be new unfavourable ocular sequelae which could escape the scrutiny of regulatory trials. The aim of this article is to report a rather surprising unilateral drug-induced inner and outer retinal atrophy in a setting of systemic administration.

Corresponding Author: DR. MEGBELAYIN, EMMANUEL O

Department of Ophthalmology,
Faculty of Clinical Sciences,
University of Uyo, Nigeria.

E-mail: favouredolu@yahoo.com, Tel: +2348036670920

Case Report

A 51-year-old male University lecturer presented with a one-month history of gradual painless loss of vision in the right eye. Defective vision was worse

during the day with associated distortion of images especially in the central region. However there was slight improvement of vision in dim illumination and at night. No micropsia, macropsia, floaters or flashes of light. There was no history of antecedent trauma, redness, pain or eye discharge. Patient had received 7 cycles of chemotherapy over one year for confirmed Chronic Lymphocytic Leukaemia (CLL). Chemotherapy was a combination of Rituximab, Fludarabine Phosphate and Cyclophosphamide administered via an intravenous port on the right upper anterior chest wall. Six months after the full course of chemotherapy, deterioration in vision was noted and became profound a month before presentation.

A known diabetic for 7 years and hypertensive for 3 years on treatment with well-controlled glycemic and blood pressure levels. Currently on Amlodipine 10mg daily, Lisinopril 5mg daily tablets and Glibenclamide 5mg daily. Review of systems was not contributory.

Examination

Systemic

This was essentially normal including the cardiovascular system.

Ocular

Anterior segments in both eyes were within normal limits.

Best corrected visual acuities (BCVA) were Right Eye: 6/18 and Left Eye: 6/6. Intra ocular pressures (IOPs) were 9mmHg and 10mmHg for right and left eyes respectively. Dilated Fundus examination with 90D and Indirect Ophthalmoscope revealed a normal left eye. On the other hand, the right eye, the same side cytotoxics were administered, showed a dull-looking retina with generalised narrowing of retinal arterioles. Retinal veins showed normal calibre up to the periphery and no peripheral treatable retinal lesions. Macular was thinned with retinal pigment epithelial (RPE) changes. There were no diabetic retinopathy changes. Optic Nerve Head (ONH) was also normal.

Fundus photos (figure 1) and Optical Coherence Tomography (OCT) (figure 2) were done. Unfortunately patient declined Fundus Fluorescein Angiography (FFA) on account of possible complications during the process of obtaining consent for procedure. Our facility has no OCT-angiography (OCTA) as a viable alternative.

The initial impression was chemotherapy-induced retinal arterial occlusion. However without FFA

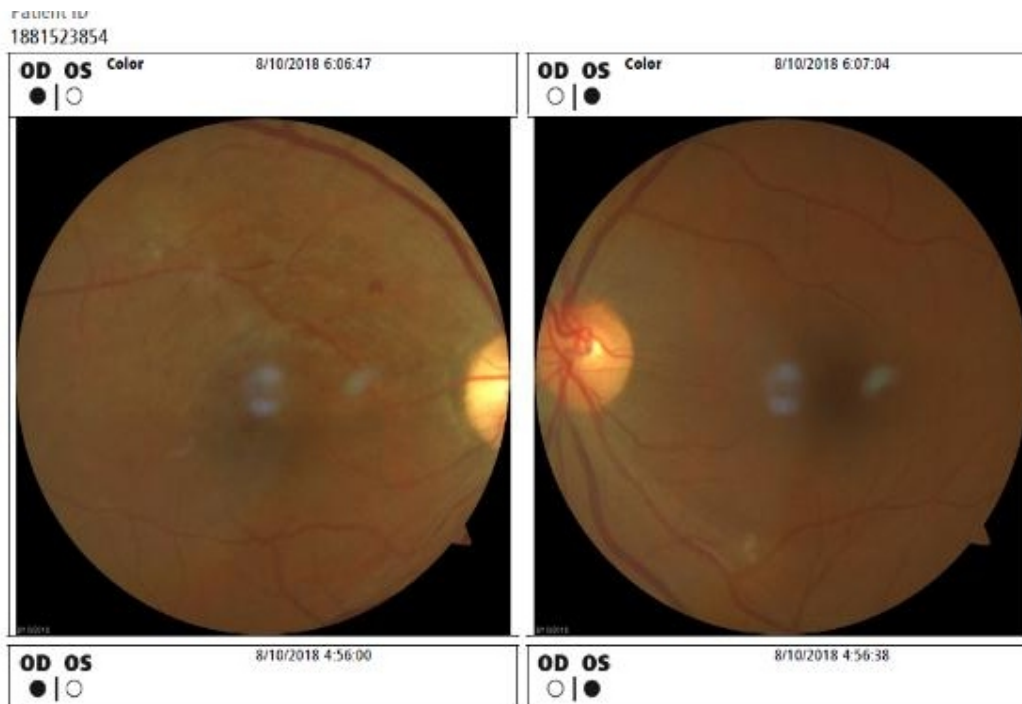


FIGURE 1: FUNDUS PHOTOGRAPHS OF RIGHT AND LEFT EYES RESPECTIVELY

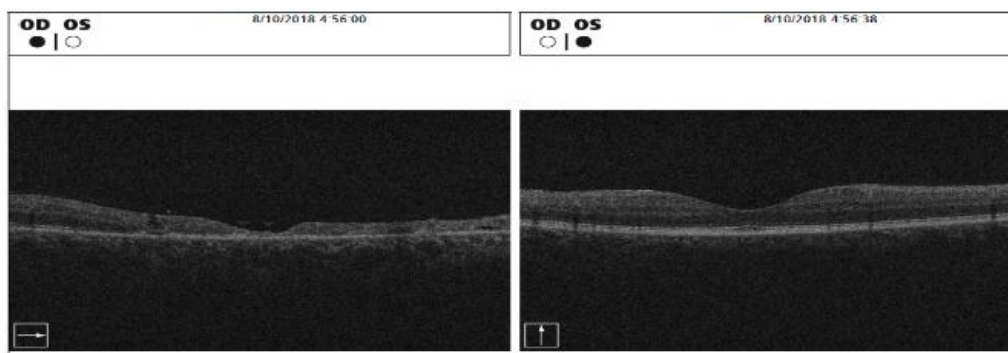


FIGURE 2: OCT OF RIGHT AND LEFT EYES RESPECTIVELY

report and with OCT that showed atrophic neurosensory retina, foveal thinning and some level of outer retinal attenuation especially the outer segment-inner segment junction, it was thought the end product of retinal assault be it vascular occlusion or direct toxicity to retinal cells, had resulted in non-specific and non-pathognomonic pan-retinal atrophy.

DISCUSSION

Rituximab, Fludarabine Phosphate and Cyclophosphamide are used as chemotherapy cocktail in the treatment of CLL.¹²⁻¹⁴ Although effective in the management of this blood malignancy, their effects on vision are sparse in literature.¹⁵⁻¹⁷ Indeed the route of administration appeared to have introduced a paradigm of unilaterality to systemically administered drugs. There are two most likely possibilities in which systemically administered drugs or condition could have unioocular manifestation. There is the possibility of occlusive vasculopathy in the contralateral spared side. In this instance, not enough blood and hence drugs reach the eye to unleash lethal effects. The second is that drug accessing systemic circulation through the right side perhaps get to eyes first before being circulated by cardiac pump mechanisms. The belief is that as the drugs get to the right eye, there is “first-pass effect” that ensures retention of active and perhaps toxic drug components. Blood reaching the left eye through recirculation by cardiac pump has depleted toxic potentials.

Although there is a remote likelihood that the primary disease, which is CLL, might have a unilateral visual effect, the challenge with multiple

drug administration is the difficulty in isolating culprit. Nonetheless, this article brings to the fore that whenever any of Rituximab, Fludarabine Phosphate or Cyclophosphamide is contemplated as a therapeutic option, detailed ocular examination and vision monitoring with serial OCT is advised.

REFERENCES:

1. Li J, Tripathi RC, Tripathi BJ. Drug-induced ocular disorders. *Drug Saf* 2008; 31(2): 127-141.
2. Moorthy RS, Valluri S. Ocular toxicity associated with systemic drug therapy. *Curr Opin Ophthalmol*. 1999;10(6):438-46.
3. To TQ, Townsend JC. Ocular toxicity of systemic medications: a case series. *Optometry*. 2000;71(1):29-39.
4. Sbeity ZH, Baydoun L, Schmidt S, Loeffler KU. Visual field changes in methotrexate therapy. Case report and review of the literature. *J Med Liban*. 2006;54(3):164-7.
5. Semmer AE, Lee MS, Harrison AR, Olsen TW. Hydroxychloroquine retinopathy screening. *Br J Ophthalmol* 2008;92:1653-5.
6. Rodriguez-Padilla JA, Hedges TR. High-speed ultra-high-resolution optical coherence tomography findings in hydroxychloroquine retinopathy. *Arch Ophthalmol*. 2007;125:775-780.
7. Kwan AS, Sahu A, Palexes G. Retinal ischaemia with neovascularization in cisplatin related retinal toxicity. *Am J Ophthalmol*. 2006;141(1):196-7.
8. Shah VA, Cassell M, Poulouse A, Sabates NR. Talc retinopathy. *Ophthalmology* 2008;115:755.

9. Ibanez HE, Williams DF, Boniuk I. Crystalline retinopathy associated with long-term nitrofurantoin therapy. *Arch Ophthalmol.* 1994;112(3):304–5
10. Rapp P, Pilon F, Chiambaretta F, et al. Bilateral uveitis with definitive hypotony caused by systemic cidofovir. *J Fr Ophtalmol.* 2003;26(7):717–19
11. Drenser K, Sarraf D, Jain A, Small KW. Crystalline retinopathies. *Surv Ophthalmol* 2006;51:535-49.
12. Plosker GL, Figgitt DP. Oral fludarabine. *Drugs.* 2003;63(21):2317–2323.
13. M. A. Marinella, Bilateral conjunctivitis due to rituximab. *Annals of Pharmacotherapy* 2007; 41:1318.
14. Kazokoglu H, Saatci O, Cuhadaroglu H, Eldem B. Long-term effects of cyclophosphamide and colchicine treatment in Behcet's disease. *Ann Ophthalmol.* 1991;23:148–51.
15. Ding X, Herzlich AA, Bishop R, Tuo J, Chan C. Ocular Toxicity of Fludarabine. *Expert Rev Ophthalmol.* 2008; 3(1): 97–109.
16. Iaccheri B, Androudi S, Bocci EB, Gerli R, Cagini C, Fiore T: Rituximab treatment for persistent scleritis associated with rheumatoid arthritis. *Ocul Immunol Inflamm* 2010;18:223-225.
17. Durrani K, Papaliadis GN, Foster CS. Pulse IV cyclophosphamide in ocular inflammatory disease: efficacy and short-term safety. *Ophthalmology.* 2004;111:960–965.