



The use of harmonic scalpel in thyroid surgery in a tertiary hospital, south-south, Nigeria – early outcomes assessment

Peter I. Agbonrofo¹ and Omorodion O. Irowa¹

¹Lecturer/ Consultant General Surgeon, Department of Surgery, University of Benin/ University of Benin Teaching Hospital, Benin City, Nigeria.

Abstract

Context: The advent of surgical energy devices has brought innovations with their use in thyroid surgeries. Despite the widespread use of Harmonic scalpel for decades since its inception in developed countries, there is a paucity of its use in low-resource countries. This report represents our early experience with Harmonic scalpel thyroidectomy in a low-resource setting.

Subjects and Methods: A 16-month audit (June 2018 – September 2019) of thyroid surgeries in a tertiary/referral health facility in South-south, Nigeria was carried out. Eleven patients underwent harmonic scalpel thyroidectomy, however, only 10 patients had complete records and were included in the study. Relevant data including age, sex, pre-operative diagnosis, type of surgery, duration of surgery, blood loss, complication and duration of hospital stay were analyzed using IBM corporation Statistical Package for the Social Sciences (SPSS) statistics for windows, version 21.0. Armonk, New York, United States of America.

Results: Median age was 36 years, 9 were female, most had non-toxic multinodular goitre (40%). Procedures include lobectomy/isthmusectomy (40%), subtotal thyroidectomy, near-total thyroidectomy, total thyroidectomy (20% each. Mean duration of surgery was 83.5±23.1mins. Mean Estimated Blood Loss was 145.0±76.2mls while 90% had mild pain. Weight of thyroid gland ranged from 99 – 420g with a median weight of 300g. Mean duration of hospital stay was 3.1±0.99 days. Transient voice change was noted in 10% of patients. These values were significantly lower than those obtained for conventional thyroidectomy during the period (one-sample t-test, p<0.001).

Conclusion: Our early experience with the harmonic scalpel in thyroidectomy has shown the device to be versatile, easy to use, safe and effective with a significant reduction in blood loss, duration of surgery, postoperative complication and improved recovery time.

Keywords: Harmonic scalpel thyroidectomy, Low- resource setting, Goitre, Thyroid gland, Nigeria.

Introduction

Thyroid surgery is common in general surgical practice. During thyroid surgery, meticulous dissection is imperative as there is a potential risk of distressing complications such as haemorrhage and upper airway

obstruction/change in voice from injuries to nerves, blood vessels and other contiguous structures.¹⁻³

Over centuries, the clamp-and-tie technique, developed by Theodor Kocher and Theodor Billroth (1873 - 1883), has been the acceptable standardized thyroid surgery technique without significant changes.^{4,5} However, the advent of energy devices in recent times has brought innovations with their use in thyroid surgeries.⁶⁻⁹ Several studies have shown excellent use in

Corresponding Author: Dr. Peter I. Agbonrofo

Department of Surgery, University of Benin/University of Benin Teaching Hospital, PMB 1111, Benin City, Nigeria.

E-mail: pagbonrofo@gmail.com, peter.agbonrofo@uniben.edu

Phone: +2348028296343

devascularisation and mobilization of the thyroid gland with reduced complication rates.^{7,8,10} The modern energy devices in surgical use include the Ligasure (advanced bipolar energy), harmonic scalpel (ultrasonic energy) and Lasers.^{11,12}

The ultrasonic harmonic scalpel was introduced in the early 1990s (Ethicon Endo-Surgery).^{13,14} It is a surgical instrument that utilizes ultrasonic vibrations at 55,000Hz to cut and coagulate tissue simultaneously with reliable haemostasis. Its precise dissection generates less lateral thermal spread and thus minimal lateral thermal damage for safer dissection near vital structures.^{11,15,16} Vessels up to 5mm in diameter are reliably sealed and divided by this device.^{11,12}

These properties make it a veritable tool in thyroid surgery where meticulous dissection is required to avoid damage to contiguous structures. However, it takes a longer time to coagulate and cut tissues than other energy devices.^{11,13}

Despite the widespread use of advanced energy devices (Ligasure /Harmonic scalpel) for decades since their inception in developed countries, their first documented use for thyroid surgery in available literature in Nigeria was in Ife in January 2016 by Arowolo et al (Ligasure device).¹⁰

The use of harmonic scalpel for thyroid surgery only started in June 2018 in the University of Benin Teaching Hospital (UBTH). This study is an audit of our early experience with the use of the Harmonic scalpel for thyroidectomy in University of Benin Teaching Hospital, Benin City, Nigeria.

Objective

To describe our early experience with the use of Harmonic scalpel for thyroidectomy in UBTH.

Methods

Study setting/population: A 16-month retrospective audit (June 2018 – September 2019) of thyroid surgeries in UBTH was carried out. The University of Benin Teaching Hospital

is a tertiary health care centre located in Benin City, Edo State, South-south of Nigeria. From its inception, it has offered surgical services which included conventional thyroid surgeries. The Harmonic scalpel Gen 11 (Ethicon Endo-Surgery, Cincinnati, Ohio, USA) was introduced in our centre in June 2018. Eleven patients had harmonic scalpel thyroidectomy, however, only 10 patients had complete records and were included in the study.

Study variable: Data on Harmonic scalpel thyroidectomies including age, sex, pre-operative diagnosis, type of surgery, duration of surgery, blood loss, complication, and duration of hospital stay were obtained.

Description of surgical procedure: Harmonic scalpel thyroidectomy was carried out with the patient under general anaesthesia with endotracheal intubation, lying supine. The neck was extended with sandbags between the shoulders and the head cradled in a head-ring. Routine skin preparation was done, thereafter standard thyroid draping was applied. A collar crease incision was made about 2 finger-breadths above the jugular notch. Superior and inferior sub-platysmal skin flaps were raised (Figure 1) and the cervical fascia was divided in the midline via harmonic scalpel dissection (Figure 2). The mobilization and devascularization of the thyroid gland began with the ligation/division of branches of the middle thyroid vein with the harmonic scalpel. Consecutively, the vessels of the superior and inferior pole were identified and similarly divided with the harmonic scalpel (Figure 3); attempts were made to identify and preserve the superior and inferior parathyroid glands. The small fibrous vascular attachments on the lateral aspect of the ipsilateral lobe were also dissected with the harmonic scalpel as they entered the thyroid capsule. Thereafter, the contralateral thyroid lobe was dissected using the same technique. The subsequent mobilization of the isthmus and pyramidal lobe completed the dissection. Haemostasis was completely secured with the harmonic scalpel. Wound drain

was inserted; the cervical fascia was sutured thereafter and the skin closure was achieved with subcuticular Vicryl or nylon suture.

Data analysis: Relevant data were analyzed using IBM corporation Statistical Package for the Social Sciences (SPSS) statistics for

windows, version 21.0. Armonk, New York, United States of America.

Ethics: The audit was carried out in accordance with the World Medical Association Helsinki declaration.

Table 1: Sex, pre-operative diagnosis and type of surgical procedure done on the participants.

Variable	n (%)
Sex	
Female	9 (90.0)
Male	1 (10.0)
Pre-operative diagnosis	
Non-toxic Nodular Goitre	3 (30.0)
Non-toxic multinodular Goitre	4 (40.0)
Toxic Nodular Goitre (Euthyroid)	1 (10.0)
Toxic Multinodular Goitre (Euthyroid)	2 (20.0)
Type of Surgical Procedure	
Lobectomy/Isthmusectomy	4 (40.0)
Sub-total thyroidectomy	2 (20.0)
Near-total thyroidectomy	2 (20.0)
Total thyroidectomy	2 (20.0)

Table 2: Mean variables for Harmonic scalpel and Conventional thyroidectomy in UBTH.

Variable	Harmonic scalpel thyroidectomy	Conventional thyroidectomy
	Mean (SD)	Mean (SD)
Duration of surgery (mins)	83.5 (23.1)	128.5 (35.5)
Estimated Blood Loss (mls)	145.0 (76.2)	359.2 (159.0)
Duration of stay (days)	3.10 (0.99)	5.3 (1.7)
Weight of gland (g)	263.8 (156.7)	107.5 (63.1)

Table 3: Comparison of mean variables for Harmonic scalpel, Conventional thyroidectomy in UBTH (June 2018 – September 2019), Ligasure and conventional thyroidectomy in Ife.

Variable	Harmonic scalpel thyroidectomy	Conventional thyroidectomy UBTH (p-value)*	Ligasure thyroidectomy Ife (p-value)* ¹⁰	Conventional thyroidectomy Ife (p-value)* ¹⁰
Duration of surgery (mins)	83.5	128.5 (<0.001)	59.0 (0.008)	128.0 (<0.001)
Estimated Blood Loss (mls)	145.0	359.2 (<0.001)	116.0 (0.259)	328 (<0.001)
Duration of stay (days)	3.1	5.3 (<0.001)	1.9 (0.004)	3.55 (0.186)
Weight of gland (g)	263.8	107.5 (0.090)	121.0 (0.111)	121.0 (0.111)

*one-sample t-test, bold p-values indicate a statistically significant difference between the harmonic scalpel mean and the reference mean.

Note (Caution): normality is assumed for all the variables, and not strictly applied.

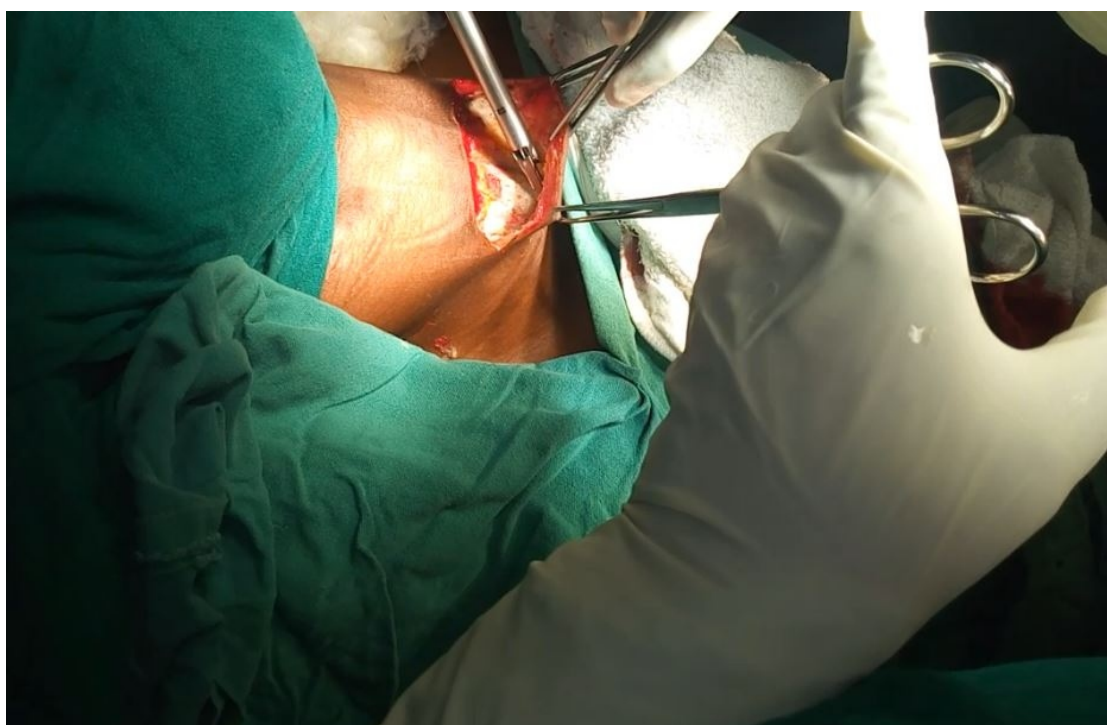


Figure 1: Raising the inferior sub-platysmal flap with the harmonic scalpel.

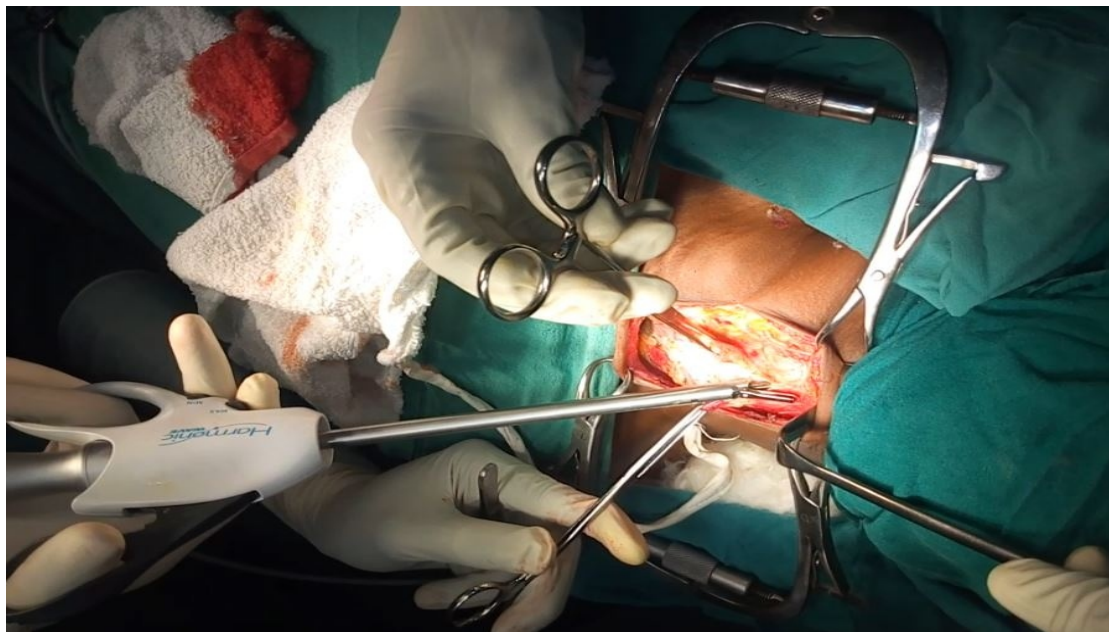


Figure 2: Division of the cervical fascia in the midline with harmonic scalpel.

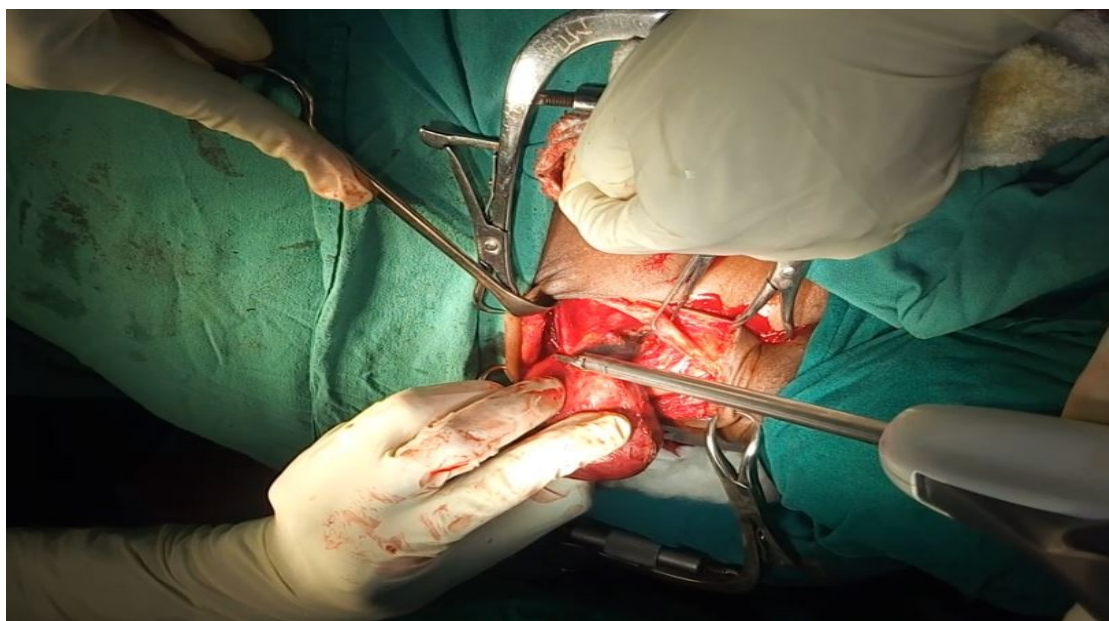


Figure 3: Division of Inferior thyroid vessels with the harmonic scalpel

Results

Over the 16 months, a total of 63 thyroidectomies were carried out. Eleven (17.5%) of these patients had thyroidectomy using the Harmonic Scalpel Gen 11. However, 10 harmonic scalpel thyroidectomy patients had complete records and were included in the study.

Age range was 27 – 73years with a median age of 36 years. Other variables are summarized in Tables 1,2 and 3.6

Mean duration of surgery was 83.5 ± 23.1 mins with a range of 50 – 115mins.

Estimated Blood Loss (EBL) range was 50 – 250mls; mean EBL was 145.0 ± 76.2 mls. There was no significant difference in blood loss between patients undergoing the different

modalities of thyroidectomy.

Weight of thyroid gland ranged from 99 – 420g with a median weight of 300g.

Nine out of 10 patients (90%) had mild pain, 1 (10%) patient was documented to have moderate pain.

Range of duration of stay was 2 – 4 days; Mean duration of stay was 3.1±0.99 days

Post-op complication occurred in 1 (10%) patient with transient voice change.

Discussion

Most patients in this study were females (90%) which is consistent with the high prevalence of thyroid diseases in females.

The harmonic scalpel was used successfully in the various types of thyroid procedures in our report. Most patients had Lobectomy/Isthmusectomy (40%) while subtotal thyroidectomy, near-total thyroidectomy and total thyroidectomy were of equal proportion (20% each). This buttresses the versatility of the device in thyroid surgery. Various studies have previously demonstrated the use of harmonic scalpel in all thyroid surgeries.^{6,7,14,17,18}

The mean duration of surgery (83.5±23.1mins) was much shorter than that for the conventional technique in UBTH (128.5mins) and in Ife (128mins) ($p<0.001$).¹⁰ This may be as a result of less instrument exchanges as the harmonic scalpel divides and coagulates tissues simultaneously.^{12,13,18} However, the mean duration for harmonic scalpel thyroidectomy in our study was significantly longer than 58mins for the Ligasure technique in Ife ($p=0.008$).¹⁰ This is in keeping with reports of longer operation time with the use of harmonic scalpel compared to other modern advanced energy devices.^{11,12,13} The learning curve of the use of the harmonic scalpel (being a novel device in our facility) could also account for the longer duration than the Ife Ligasure study. The authors expect shorter operative times as expertise is gained with its continuous use. In addition to

reducing the patient's exposure to the stress of anaesthesia, the shorter duration of harmonic scalpel thyroidectomy reduces the discomfort of the surgeon and enhances the possibility of adding more patients to a surgical list.^{6,19}

There was no significant difference in blood loss between patients undergoing the different modalities of thyroidectomy in this study. Mean EBL of 145±76.2mls was comparable to 116mls from Ligasure thyroidectomy reported in Ife ($p=0.259$) but significantly lower than 359mls from conventional knot tying technique in UBTH, 328 mL in Ife and 334.3 ± 168 mL in Irrua ($p<0.001$).^{10,20} Reports of several other studies have corroborated this finding,^{3,6,14,17,21} underscoring the significant haemostatic efficacy of these advanced energy devices in surgery. This significantly reduced blood loss reduces the need for blood transfusion and thus grouping and cross-matching requirements. The use of this device may as well be a strategy to conserve blood in low resource settings where blood is scarce.

Post-op pain was mild in 90% of patients who had harmonic scalpel thyroidectomy while 10% had moderate pain. This corroborates the finding by Litta P et al and other reports of reduced post-operative pain with the use of the Harmonic scalpel.^{13,14,22} This could be attributed to the reduced tissue destruction from the low lateral thermal spread and precise dissection of the harmonic device.¹¹

Harmonic scalpel thyroidectomy was associated with significantly lower post-operative duration of hospital stay (Mean of 3.1±0.99 days) than the conventional technique in UBTH (mean of 5.3days; $p<0.001$) and comparable to the conventional technique in Ife (mean of 3.55days; $p=0.186$).¹⁰ However, it is significantly longer than 1.9days reported in the Ife Ligasure series ($p=0.004$).¹⁰ This could be as a result of routine use of wound drains for thyroidectomy in our study; requiring removal before discharge.

Post-op complication was noted in one (10%)

patient with a transient change in voice; possibly due to neuropraxic injury. She had complete recovery within 4 weeks. Others had no complications during the 3 months follow-up. This reduced post-op complication rate is comparable to that reported in the Ife Ligasure study (10%) and several other studies involving the use of advanced energy devices in thyroid surgery;^{10,11,14,17} but lower than that of the conventional technique in UBTH (16%). The precise dissection and less lateral thermal spread associated with the use of advanced energy devices could be responsible for this finding.^{11,13}

Limitations

This study is a retrospective non-randomised/controlled audit of our early experience with a relatively novel and expensive technique in a low resource setting with an attendant sample size. Future prospective randomized controlled studies will be required to further corroborate its findings.

Conclusion

Our early experience with the harmonic scalpel in thyroidectomy has shown the device to be versatile, easy to use, safe and effective with a significant reduction in blood loss, duration of surgery, postoperative complication and improved recovery time.

Acknowledgements

The contribution of Stanley Okugbo and Gregery Oko-oboh in the preparation of this manuscript is hereby acknowledged.

References:

- Burkey SH, Van Hereden JA, Thompson GB et al. Reexploration for symptomatic hematomas after cervical exploration. *Surgery* 2001; 130: 914–919.
- Afolabi AO, Ugwu BT. The Thyroid and Parathyroid glands. In: Achampong EQ, Naaeder SB, Ugwu BT eds. *BAJA's Principles and Practice of Surgery including Pathology in the Tropics*. 5th ed. Accra: Ghana Publishing Cooperation; 2015:361–377
- Cordón C, Fajardo R, Ramírez J et al. A randomized, prospective, parallel group study comparing the Harmonic Scalpel to electrocautery in thyroidectomy. *Surgery* 2005; 137: 337–41.
- Hannan SA. The magnificent seven: a history of modern thyroid surgery. *Int J Surg* 2006; 4:187–91.
- Becker WF. Presidential address: pioneers in thyroid surgery. *Ann Surg* 1977;185:493–504
- Ortega J, Sala C, Flor B, Lledo S. Efficacy and Cost-Effectiveness of the UltraCision® Harmonic Scalpel in Thyroid Surgery: An Analysis of 200 Cases in a Randomized Trial. *Journal of Laparoendoscopic & Advanced Surgical Techniques* 2004; 14(1): 9–12. doi:10.1089/109264204322862289
- Takami H, Ikeda I, Niimi M. Ultrasonically activated scalpel for subtotal thyroidectomy in Graves' disease. *Am J Surg* 1999; 178:433.
- Siperstein AE, Berber E, Morkoyun E. The use of the harmonic scalpel vs conventional knot tying for vessel ligation in thyroid surgery. *Arch Surg* 2002; 137:137-42.
- Petrakis IE, Kogerakis NE, Lasithiotakis KG, Vrachassotakis N, Chalkiadakis GE. LigaSure versus clamp-and-tie thyroidectomy for benign nodular disease. *Head Neck* 2004; 26: 903-9.
- Arowolo OA, Olasehinde O, Adisa AO et al. Early experience with ligasure thyroidectomy in a Nigeria Teaching Hospital. *Niger J Surg* 2019; 25: 64-9.
- Obonna GC, Mishra RK. Differences between Thunderbeat, LigaSure and Harmonic Scalpel Energy System in Minimally Invasive Surgery. *World J Lap Surg* 2014; 7(1):41-44
- Seehofer D, Mogl M, Boas-Knoop S et al. Safety and efficacy of new integrated bipolar and ultrasonic scissors compared to conventional laparoscopic 5-mm sealing and cutting instruments. *Surg Endosc* (2012) 26:2541–2549. DOI 10.1007/s00464-012-2229-0
- Sandham J. The harmonic scalpel. *EBME and Clinical Engineering articles* 2011

- <https://www.ebme.co.uk/articles/clinical-engineering/the-harmonic-scalpel>. Accessed 14th October, 2019.
14. Ecker T, Carvalho AL, Choe JH et al. Hemostasis in thyroid surgery: harmonic scalpel versus other techniques - a meta-analysis. *Otolaryngology*. 2010;143(1):17–25
 15. McCarus SD. Physiologic mechanism of the ultrasonically activated scalpel. *J Am Assoc Gynecol Laparosc* 1996; 3: 601–608.
 16. Dutta DK and Dutta I. The Harmonic Scalpel. *J Obstet Gynaecol India*. 2016; 66(3): 209–210. Published online 2016 Feb 26. doi: 10.1007/s13224-016-0850-x
 17. Shemen L. Thyroidectomy using the harmonic scalpel: analysis of 105 consecutive cases. *Otolaryngol Head Neck Surg* 2002; 127:284–288.
 18. Miccoli P, Berti P, Raffaelli M et al. Impact of harmonic scalpel on operative time during video-assisted thyroidectomy. *Surg Endosc* 2002; 16:663–666. 12.
 19. Sebag F, Fortanier C, Ippolito G et al. Harmonic scalpel in multinodular goiter surgery: impact on surgery and cost analysis. *J Laparoendosc Adv Surg Tech A*. 2009;19 (2):171-4. doi: 10.1089/lap.2008.0043.
 20. Kpolugbo J, Uhumwangho O, Obasikene G, Alili U. Blood transfusion, antibiotics use, and surgery outcome in thyroid surgery: Experience from a suburban center in Nigeria. *Niger J Clin Pract* 2012; 15:458-61.
 21. Siu JM, McCarty JC, Gadkaree S et al. Association of Vessel-Sealant Devices vs Conventional Hemostasis with Postoperative Neck Hematoma after Thyroid Operations. *JAMA Surg*. 2019; 154 (11):e193146. doi:10.1001/jamasurg.2019.3146
 22. Litta P, Fantinato S, Calonaci F, et al. A randomized controlled study comparing harmonic versus electrosurgery in laparoscopic myomectomy. *Fertil Steril*. 2010; 94: 1882 – 1886 . doi : 10.1016/j.fertnstert.2009.08.049.