

---

## OVARIAN ECTOPIC PREGNANCY IN AKTH: CASE SERIES

Shuaibu Adavuruku Danjuma, \*\*Taiwo Nafia Abolanle\*,  
Muhammad Zakari\*\*, Murtala Yusuf\*\*

\*Department of Obstetrics and Gynaecology, Aminu Kano Teaching Hospital, Kano

\*\* Department of Obstetrics and Gynaecology, Bayero University, Kano.

---

### ABSTRACT

**Background:** Ovarian pregnancy is a rare form of extra-uterine pregnancy. Clinical presentation varies from asymptomatic to life threatening ones.

**Case:** We report two cases of multiparous patients who presented with ruptured primary ovarian ectopic pregnancy with haemoperitoneum managed in Aminu Kano Teaching Hospital, Kano. The diagnosis was made at surgery and they had salpingo-oophorectomy. Histopathological result confirmed the diagnosis.

**Conclusion:** The most common clinical factor that gives high index of suspicion is the use of IUD.

**Keywords:** Ovarian Pregnancy, IUD, Laparotomy, Aminu Kano Teaching Hospital, Kano

### INTRODUCTION

Ovarian ectopic is a rare variant of ectopic pregnancy occurring in

1 –3% of all ectopic pregnancies.<sup>1</sup> The incidence is on the rise with causes attributable to better diagnostic modalities, increase use of intra-uterine devices, ovulation induction drugs and assisted reproductive techniques.<sup>2</sup>

Accurate pre-operative diagnoses of primary ovarian ectopic pregnancy is challenging and undoubtedly further delay may lead to serious maternal morbidity or even mortality.

### Case 1

Mrs M.H, a 37years old G<sub>3</sub>, P<sub>2</sub> + 0 2A last child birth was 18 months before presentation who presented at gynaecological unit of Aminu

---

Corresponding Author: DR. TAIWO NAFIA ABOLANLE  
Department of Obstetrics and Gynaecology,  
Aminu Kano Teaching Hospital,  
Kano, Nigeria  
E-mail: taiwonafia13@gmail.com

Kano Teaching Hospital with complaint eight weeks of Amenorrhea, lower abdominal pain one day and vaginal bleeding of 12 hours duration.

She presented with sudden onset of severe left lower abdominal pain associated with vaginal bleeding. There was no history of fever, nausea, vomiting, vaginal discharge or urinary symptoms. Her previous menstrual cycle was regular. She had term uncomplicated pregnancies and had spontaneous vaginal delivery. However she had IUCD for contraception following her last delivery which she removed 4 weeks prior to presentation following a positive pregnancy test.

There was history of dizziness but no fainting attack. She had ultrasound scan done before presentation and took Paracetamol. On examination, she was afebrile (36.6°C) and moderately pale. She was haemodynamically unstable, the pulse rate was 124bpm and blood pressure was 70/40mmHg. The abdomen was moderately distended moving minimally with respiration. There was generalized abdominal tenderness, rigidity and guarding. Speculum examination was normal. Vaginal examination revealed fullness of pouch of Douglas and cervical motion tenderness was positive.

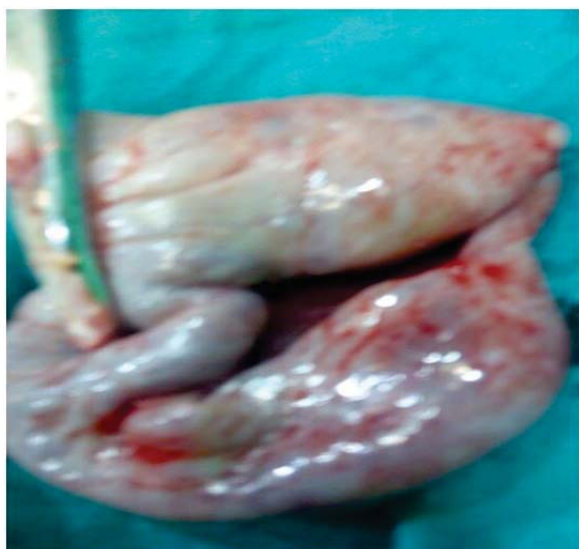The urinary Beta Human Chorionic Gonadotropin(BHCG) was positive. Haemoglobin concentration was 7.8g/dl. Pelvic USS result which she presented with showed empty uterus, haemoperitoneum and a left complex adnexal mass measuring 7 x 6 x 5cm.

Emergency laparotomy was done with a preoperative provisional diagnosis of ruptured left tubal ectopic pregnancy after informed consent was taken. Intra-operatively, uterus was bulky, both tubes were normal. Haemoperitoneum was 1.2L. The right ovary was normal. Left salpingo-

oophorectomy was done. The patient had an uneventful postoperative recovery, the diagnosis of ruptured ovarian ectopic was made according to Spiegelberg's criteria.

Macroscopic examination showed ovarian specimen measuring 5 x 4 x 3cm, weighing 10g. The cross section revealed haemorrhagic surface. Histopathological examination review section of ovarian tissue showing cyst lined by luteinized granulosa cells, chorionic villi, trophoblastic cells and corpus luteum within the stroma of the ovary. The sections from the fallopian tube showed no evidence of gestational tissue.

Therefore, diagnosis of primary ruptured ovarian ectopic pregnancy was confirmed. Three units of O+ blood grouped and cross-matched for her were transfused in the immediate postoperative period. She was counseled on intra-operative findings, the haemoglobin concentration at discharge (5<sup>th</sup> day) was 10.2g/dl. She was followed over six months and she was asymptomatic with regular menstrual cycle.



## Case 2

The second case is Mrs G.Z, a 25 years old G<sub>2</sub> P<sub>1</sub>+OA1 last child birth was 22months before presentation who presented at gynaecological unit of Aminu Kano Teaching Hospital with complaint of 6weeks Amenorrhea and lower abdominal pain of 6 hours duration.

She presented with sudden onset of

excruciating lower abdominal pain associated with spotting of blood from the vagina. There was no history of fever, nausea, vomiting, vagina discharge or urinary symptoms. Her previous menstrual cycle was regular. She had emergency caesarian section on account of severe preeclampsia at term. Intra-uterine contraceptive device was inserted following delivery and was removed 2 weeks before presentation. There was no history of dizziness or fainting attack.

On examination, she was afebrile (37.2<sup>o</sup>C), mildly pale. The pulse rate was 108bpm and blood pressure was 100/60mmHg. The abdomen was full move with respiration with healed Pfannenstiel scar. There was vague generalize abdominal tenderness which was more in the suprapubic region and left iliac fossa. Speculum examination was normal. Vagina examination revealed left adnexal mass, no fullness of pouch of Douglass and cervical motion tenderness was positive.

The urinary BHCG was positive. Haemoglobin concentration was 8.9g/dl.

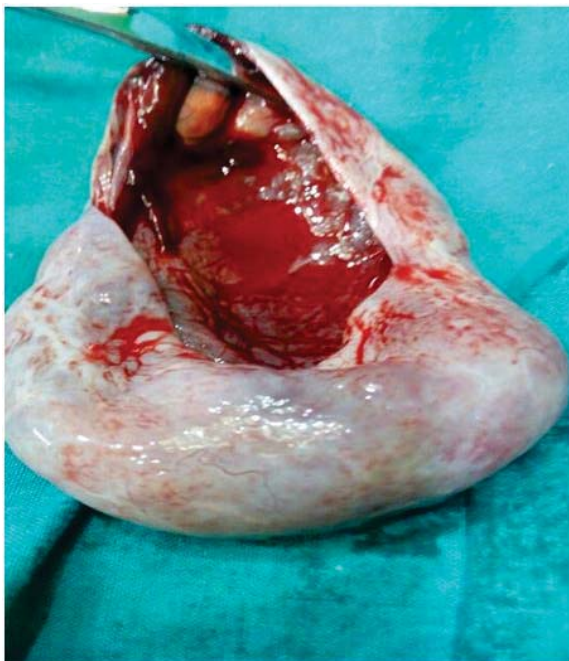
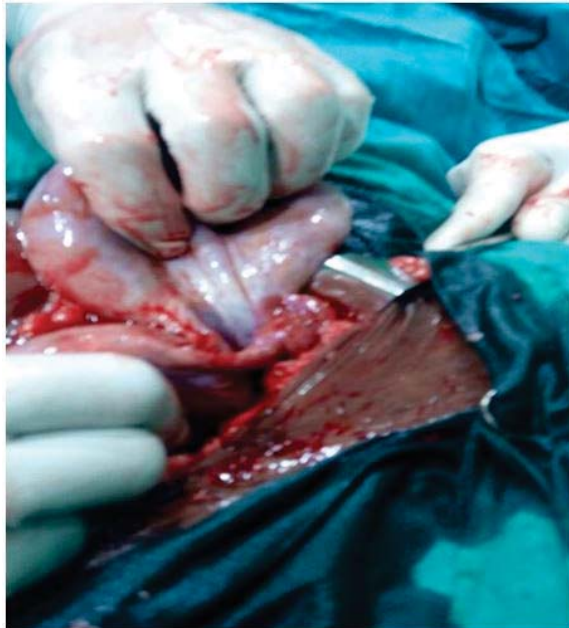
Pelvic ultrasonography result showed bulky uterus but empty with a complex left adnexal mass measuring 5.1 x 4.1 x 3.0cm with significant fluid collection in the pouch of Douglas.

Emergency laporatomy was done with a preoperative diagnosis of ruptured left tubal ectopic pregnancy after informed consent was obtained. Intra-operatively, uterus was normal, both tubes were grossly normal. A left ruptured ovarian ectopic was found. Haemoperitoneum was 300mls. The right ovary was normal. Left salpingo-oophorectomy was done. The patient had an uneventful postoperative course.

Postoperatively, the diagnosis of ruptured ovarian ectopic was made according to Spiegelber's criteria. Macroscopic examination showed ovarian specimen with open cystic area measuring 4.0 x 3.2 x 2.5cm weighing 11g. The cross section showed, corpus luteum and blood clots were seen. Microscopic examination showed ovarian tissue with cystic lesion lined by luteinized granulosa cells, trophoblastic cells, chorionic villi and area of haemorrhage. The sections

from the fallopian tube showed no evidence of gestational tissue.

Thus, the diagnosis of primary ruptured ovarian ectopic pregnancy was confirmed. The postoperative haemoglobin concentration was 8.5g/dl and was not symptomatic, so she was not transfused. She was counseled on intra-operative finding and contraception.



## DISCUSSION

An ectopic pregnancy is defined as implantation and development of an embryo

outside the uterine endometrium.<sup>1</sup> The most common location continues to be fallopian tube (95%), then rare sites include the ovary (3.2%) or abdomen (1.3%).<sup>4</sup>

Ovarian ectopic pregnancy is a rare and life threatening condition and its early detection is perhaps the most difficult compared to other forms of extra-uterine pregnancies.<sup>3</sup>

Ovarian pregnancy, may occur if fertilization occur in the peritoneal cavity and then fertilized ovum implanted on the ovary or fertilization occur in the tube then via tubal abortion or rupture, product of conception implanted on ovarian surface.<sup>5</sup>

It is a rare entity but the incidence has been on the rise due to better diagnostic modalities, wider use of contraceptive IUD, ovulation induction drugs, assisted reproductive technique like

Invitro-fertilization and embryo transfer (IVF-ET), and empty follicle syndrome. Endometrioses, PID, smoking have also been implicated.<sup>6</sup> The two cases had history of recent use of IUD. However, few reported cases had no underlying causes, they happened by chance.<sup>3</sup>

Ovarian ectopic occurs in young female, similar to current cases and clinical presentation vary from asymptomatic to life threatening one. The two cases presented with features of acute abdomen. The diagnosis still remains a problem and a challenge to gynaecologists. Many times, it is misdiagnosed clinically as ruptured tubal ectopic pregnancy and diagnosis is often made intra-operatively and confirmed by histopathological examination.<sup>2,7</sup> These were seen in the two cases described. It may be important to note that ovarian pregnancy can terminate several days before expected date of menstruation without history of amenorrhea.<sup>2</sup>

The diagnostic dilemma can be overcome sometimes before rupture by the use of high resolution transvaginal ultrasonography followed by diagnostic laparoscopy. These were not done for the two (2) cases reported because they presented with features suggestive of acute abdomen.<sup>8,9</sup>

Intra-operately, diagnosis of ovarian ectopic

was made using the Spiegelberg's criteria which was later confirmed postoperatively by histological report. The mainstay of surgical treatment for ovarian pregnancy is salpingo-oophorectomy or conservative surgical management like ovarian wedge resection depending on the extent of tissue destruction. However salpingo-oophorectomy of the affected side was done for the two reported cases after thorough assessment of vitality of ovarian tissue.

The other treatment option is methotrexate (conservative treatment) but was not considered because the two cases reported were ruptured and needed immediate surgery.<sup>10,11,12</sup>

In conclusion, ovarian ectopic is a rare variant of ectopic pregnancy which is not only difficult to diagnose but often misdiagnosed as tubal ectopic pregnancy. Most often diagnoses is made intra-operatively and confirmed by histopathological report. The management is essentially surgical however medical management with methotrexate therapy has been reported for few selected cases.

## REFERENCES:

1. Ghasemi T, Leila H, Zaynab H, Mojdeh G. Ovarian ectopic pregnancy: A rare case. *Iran J Reprod Med.* 2014;12(4):281-284.
2. Jasmina B, Pallavee P, Sunita S. Diagnostic dilemma in ovarian pregnancy: A case series. *Journal of Clinical and Diagnostic research.* 2015;9(4):QR01-QR03.
3. Samiee-Rad F, Ziaee-Ardestani M, Kalhor M, Keshavarvi B. Primary ovarian ectopic pregnancy: A case report. *Biotech Health Sci.* 2017;4(1):e41605.
4. Bouyer J, Coste J, Fernandez H, Pouly JL, Job-Spira N. Sites of ectopic pregnancy: a 10 year population based study of 1800 cases. *Hum Reprod* 2002;17:3224-3230.
5. Manjula N, Sundar G, Shetty S, Sujani B, Mamatha D, editors. A rare case of a ruptured ovarian pregnancy. *Proceedings in Obstetrics and Gynaecology.* 2010;pp1-5.
6. Sharma N, Vasudevam S. Ruptured ovarian ectopic pregnancy: Case Report and review

- of literature. *Int. J. Curr. Microbiol. App.Sci.* 2014;3(9):294-299.
7. Hallet JG. Primary ovarian pregnancy: A report of twenty-five cases. *Am J Obstet Gynecol.* 1982;143:59-60
8. Comstoc C, Huston K, Lee W. The ultrasonographic appearance of ovarian ectopic pregnancies. *Obstet Gynecol.* 2005;105(1):42-45.
9. Ghi T, Banfi A, Marconi R, Laco PD, Pilu G. Three dimensional sonographic diagnosis of ovarian pregnancy. *Ultrasound Obstet Gynecol.* 2005;26:102-04.
10. Yilmaz O, Kucur SK, Yardim D, Davas I, Polat N. Diagnosis and clinical approach in primary ovarian ectopic pregnancy: A case report and review of literature. *Dicle Med. J.* 2013;40(1).
11. Adeyemi AS, Afolabi AF. Extrauterine foetal death misdiagnosed as missed abortion. *Ann Trop Med Public Health.* 2012;5(6):597.
12. Birge O, Erkan MM, Ozbey EG, Arslan D. Medical management of an ovarian ectopic pregnancy: a case report. *Journal of Medical case Reports.* 2015;9:290